

## Revisited Anterolateral Thigh Free Flaps For Reconstructive Microsurgery : One Year Evaluation

Parintosa Atmodiwirjo, Siti Handayani, Shelly Madona Djaprie  
Jakarta, Indonesia

**Background:** Extensive soft tissue defects present a difficult problem to the plastic surgeon as they are usually associated with exposed important structures such as vessels, nerves, tendons, joint cavity or bone. Reconstruction of soft tissue defects have a wide range of therapeutic options. We reconstructed soft tissue defect in many areas using free anterolateral thigh flap (ALTF).

**Methods:** From Februari 2009 - 2010, 9 cases of soft tissue defects in the face, neck, leg and foot of various etiologic factors were admitted to the plastic and reconstructive surgery unit, Cipto Mangunkusumo general hospital.

**Results:** Trauma is the commonest cause of soft tissue defects of the lower extremity, followed by tumors. The cruris was the commonest site (4 cases, 44,4%). Flap success rate was 66,67 %. Failure was reported 1 cases in this study due to vein compromise.

**Conclusion:** In our hospital, we are quite familiar with Anterolateral thigh flap (ALTF) even though the case is limited. Anterolateral thigh flap (ALTF) is used for reconstruction of various simple and complex soft tissue defects, for big and small defects with cavity (orbita).

**Keywords:** ALT flap, soft tissue defects

**Latar belakang:** Suatu defek jaringan lunak yang luas, merupakan kesulitan tersendiri bagi para ahli bedah plastik, dikarenakan hal tersebut biasanya berhubungan dengan struktur – struktur penting yang terpapar, seperti pembuluh darah, syaraf, tendon, sendi maupun tulang. Rekonstruksi terhadap defek jaringan lunak yang luas memiliki pilihan terapi yang luas. Dalam hal ini kami melakukan rekonstruksi jaringan lunak di berbagai area menggunakan Anterolateral Thigh flap (ALTF).

**Metodologi:** Dari Februari 2009 – 2010, terdapat 9 kasus defek jaringan lunak di wajah, leher, ekstremitas bawah dan kaki yang disebabkan oleh berbagai faktor penyebab, yang datang ke Bagian Bedah Plastik dan Rekonstruksi, RSCM.

**Hasil:** Trauma merupakan penyebab tersering defek pada jaringan lunak di daerah ekstremitas bawah, kemudian defek yang disebabkan oleh tumor. Kruris merupakan area paling sering (4 kasus, 44,4%), angka keberhasilan flap 66,67 % . Pada penelitian ini, hanya 1 kasus yang dilaporkan mengalami kegagalan.

**Kesimpulan:** Penggunaan anterolateral flap (ALTF) cukup familiar di rumah sakit kami walaupun kasusnya terbatas. Anterolateral thigh flap (ALTF) digunakan untuk merekonstruksi berbagai macam defek jaringan lunak dari yang sederhana sampai yang kompleks, serta defek yang kecil maupun besar disertai kavitas (orbita)

**Kata Kunci:** ALT flap, soft tissue defects

Extensive soft tissue defects present a difficult problem to the plastic surgeon as they are usually associated with exposed important structures such as vessels, nerves, tendons, joint cavity or bone. Trauma is the commonest cause of soft tissue defects of the lo-

wer extremity, followed by tumors, where as venous ulcers contributes the majority up to 70% of all leg ulcers. Reconstruction of soft tissue defects have a wide range of therapeutic options, starting from skin grafting over muscles, intact fascia, tendons and periosteum and flaps.

Since its introduction in the late 1950s, the free flap has evolved to the method of cho-

*From Division of Plastic Surgery, Department Of Surgery, Cipto Mangunkusumo General National Hospital, Universitas Indonesia.*

*Presented at the 14th Indonesian Association Of Plastic Surgery, Balikpapan, Indonesia, and the XV<sup>th</sup> Congress International Confederation for Plastic Reconstructive and Aesthetic Surgery, Vancouver, British Columbia (Canada)*

**Disclosure:** This work did not receive support from any grant, and no author has any financial interests

ice as a means to reconstruct or close large defects. In the last decade, success rates of 95 percent and higher have been reported. Despite these improving success rates, microvascular failure remains a costly disaster<sup>2</sup>.

The Anterolateral Thigh Flap (ALTF) was introduced in Asia and has gained international popularity because of a recent shift toward perforator flaps. The versatility of the Anterolateral thigh flap hinges on the ability to harvest multiple tissue components in various combinations; the reliable size and position of the perforators supplying the large skin paddle; and the long, wide caliber pedicle<sup>4</sup>.

ALTF is relatively easy to harvest once the technique of perforator flap dissection has been learned. It has a reliable blood supply despite some anatomic variability, it is pliable and can be thinned to a significant degree without compromising blood supply, and can provide a long pedicle with large diameter vessels. It can also be used as a flow through flap, and, because of its unique position, allows for a two-team approach to the reconstruction of most defects in the body. The flap can also provide different tissue components such as muscle, fascia, and skin in a variety of combinations<sup>5</sup>.

The aim of our work is to evaluate reconstruction of major soft tissue defects in the face, neck, leg and foot using ALTF in Ciptomangunkusumo general hospital between Februari 2009 to 2010.

### Anterolateral Thigh Flap (ALTF)

In 1984, Song and coworkers described the thigh as a donor site for three new flaps, which they raised from its posterior, anteromedial, and anterolateral aspect. Of these three flaps, ALTF became most popular, especially in head and neck reconstruction.

Although originally described as a fasciocutaneous flap nourished by a septocutaneous perforator of the descending branch of the lateral circumflex femoral artery, the design of the flap significantly depends on the course and location of the cutaneous vessels, the anatomy of which can vary considerably. Because of the fact that the perforator often runs through the vastus lateralis muscle instead of strictly along the intermuscular septum, parts of the vas-

tus lateralis muscle have to be included in the flap in these cases.

An important variation of designing ALTF was introduced by Kimura et al. in 1996, who performed a primary radical thinning procedure, only leaving a small cuff of fatty tissue around the perforator. With this procedure, ultrathin flaps were created, which are very useful to cover superficial skin defects.

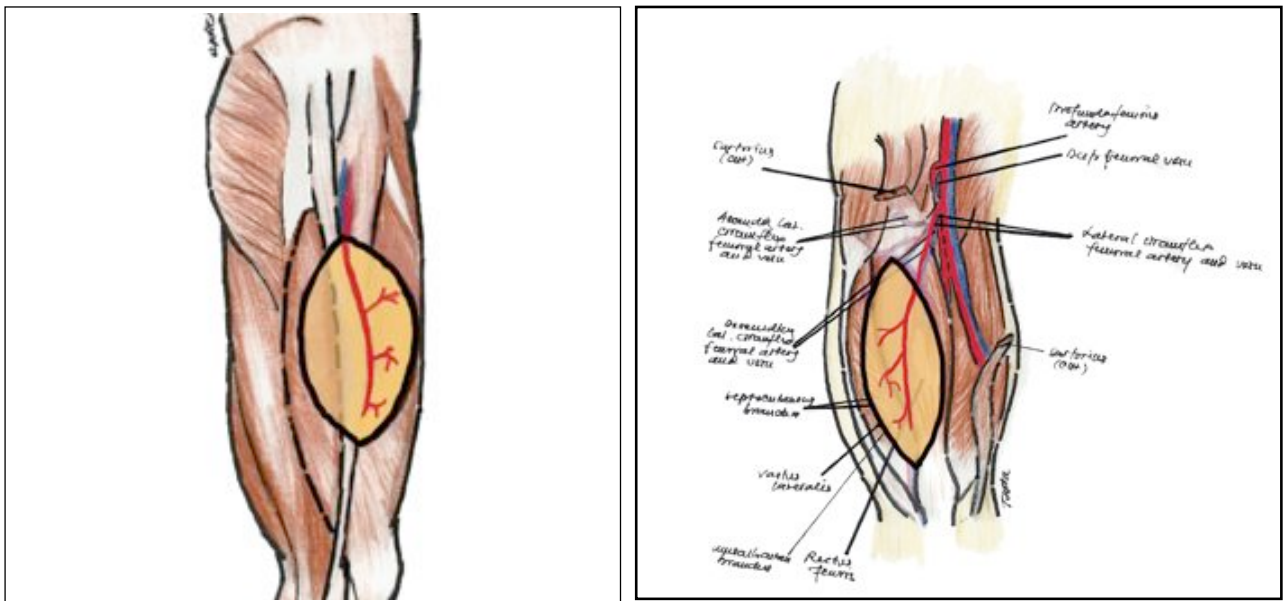
In 2002, Wei et al. published a series of 672 ALTF with a total flap failure in only 12 patients. An even larger number of 1,284 patients presented by Gedebou and Wei in the same year, who described the ALTF flap as one of the most useful soft-tissue flaps, especially in head and neck reconstruction<sup>6</sup>.

The donor site can be closed primarily or covered with a split-thickness skin. Maximum to close primarily is 8 cm. Primary closure is more difficult in the proximal and distal<sup>5</sup>. For direct closure of a donor site, after subcutaneous release of the flap margin, the largest available dimensions are 8 cm in length and 4 cm in width<sup>7</sup>.

### Anatomy

The arterial and venous blood supply of the flap comes from branches issuing from the femoral artery and returning to the femoral vein. The artery at the origin is the lateral thigh circumflex artery. One of the collateral branches of this vessel is the descending branch of the circumflex artery, which leaves the lateral thigh circumflex artery on its lateral side, gliding beneath the rectus femoris and in front of the vastus lateralis muscles. At this level, the muscular branches to the different segments of the quadriceps leave the main axis of the artery, which courses downward and laterally. The cutaneous branch follows this intermuscular space, lying on the vastus lateralis muscle. The vessel crosses the anterolateral thigh aponeurosis and divides into two axial cutaneous branches (proximal and distal), which have a longitudinal axis and give off many cutaneous branches to the skin paddle.

The venous pattern of the flap has the same axis, parallel to the arterial system all the way from the skin to the intermuscular space between the vastus lateralis and rectus femoris muscle. At this level, the anatomy is more variable. In most cases, the vein remains with the



**Figure 1a-1b.** Vascular system of anterolateral thigh and standard skin paddle.

artery. Going up to the lateral circumflex vein and then to the femoral vein. In the remaining cases, the veins remains goes more medially, with a transverse axis to the superficial lateral femoral vein, ending in the greater saphenous vein proximal to the femoral vessel (Figure 1a-1b).

### Microsurgery Technique

#### Selection of Recipient Vessels

The location and length of the recipient vessels will be factored into the design and size of the flap. Recipient vessels should be away from the zone of trauma and sites of irradiation. If possible, the vessels are selected away from

the joints, since around joints the arteries have more branches and there is a valve in the vein where every tributary joins. Large recipient veins that are at least as large as the flap vein or larger (up to twice as large) are ideal (Table 1).

The site of anastomosis is chosen away from branches and away from venous valves. As a rough guide, it is preferable to avoid them within the segment of the vessel that will be included in the clamp. If there is an arterial branch very close to the site of anastomosis, it is better to divide it, because: (1) the arterial ends retract after division and if there is any undivided branch close by, it may act as a tethering restraint and cause a kink, (2) it makes clamp application and turning the vessel to

**Table 1.** Types of Microvascular Anastomosis and Number of Vessels

Recipient Arteries	ETE	ETS	Recipient Vein	ETE	ETS
Arteri Dorsalis Pedis	-	3	Comitantes	6	-
Circ. Femoralis Desc.	1	-	Saphena Magna	1	-
Temporalis Superficial	1	-	Temporalis Superficialis	1	-
Poplitea	-	1	Comitantes & Saphena Magna	1	-
Tibialis Anterior	1	-			
Desc. Genicular	1	-			
Arteri Fasialis	1	-			

suture the back wall difficult, and (3) it may act as a restraint in positioning the pedicle prior to wound closure<sup>5</sup>.

The most common suture technique is the end-to-end anastomosis. If the vessel sizes are of reasonable match, a simple triangulation technique is used to place interrupted sutures. In the triangulation technique, the first suture can be taken at the place where it is comfortable. The second suture is taken one-third of the distance or 120° from the first. When these two stay sutures are tensioned, the two front edges come together and the back edges hang down

#### **End-to-side Anastomosis**

Godina advocated the preferential use of end-to-side anastomosis in clinical practice, reasoning that an arteriotomy tends to open up due to contraction of muscle in the vessel wall and is less prone to the problem of spasm. One requirement for a comfortable end-to-side repair is the availability of a good length of flap vessel<sup>5</sup>.

Microsurgical complication is divided into three main steps: (1) failure of planning, (2) failure of execution, and (3) failure of postoperative care. The advantages of the ALTF are the ease of harvest with relatively constant anatomy, long length and large pedicle, the versatility in design with variable thickness and incorporation of various tissue components, the ability to provide sensory innervations, lack of significant donor site morbidity, and the less operative time with two-team approach. The disadvantages are the color mismatch in some patients for facial reconstruction, the presence of hair in some male patients, the skin graft requirement at donor site if greater than 8 cm width of harvested tissue, and the lack of vessels with reasonable size in rare cases<sup>5</sup>.

#### **Flap Design and Dimension**

Flap length and width are designed to meet the requirement dimensions of the recipient site defect. From that point, flap design must maintain 2:1 Length: width ratio. The maximal length available is 30 cm and the maximal width is 15 cm.

The line between the anterior superior iliac spine and the lateral border of the patella is drawn on the donor thigh and the midpoint of this line is marked. Two centimeters above this point is usually the exit point of the cutaneous perforator. The transparent pattern of the recipient defect is placed on the donor site with the site of donor perforator in the center of the flap

#### **Applications**

Thin flaps with a large surface area are ideal for resurfacing or for draping over three-dimensional or mobile structures. Such "ultra-thin" Anterolateral Thigh flaps are also suitable for defects where a contour deformity would be undesirable cosmetically (face) or functionally (dorsum of foot/ankle/hand). The ALTF is pliable enough to be folded, tubed, or packed into cavities, and the ease with which it is harvested makes it an excellent first-line emergency flap.

Recently, bulky adipofasciocutaneous anterolateral thigh flaps have been developed for selected use in breast reconstruction.

### **PATIENTS AND METHODS**

This study included 9 cases of soft tissue defects in the face, neck, leg and foot of various etiologic factors. All patients were admitted to the plastic and reconstructive surgery unit, Cip-to Mangunkusumo general hospital between Februari 2009 to 2010.

### **RESULTS**

Nine free ALTF have been performed for reconstructive of soft tissue defects in the face, neck, leg and foot. 8 flaps were successful (88, 9%) while one flaps were lost (11,1%) secondary vein compromise. In this series 5 patients were males and 4 patients were females, whose ages range from 19 to 51 years old (Table 2). The cause of the soft tissue defects was trauma (burn 1 case (11, 1%), fracture 4 cases (44,4%), tumors in 3 patients (33,3%) and infection in 1 case (11,1%) (Table 3). The site of the defect was on the face (1 case), neck (1 case), cruris (4 cases) and pedis 3 cases (Table 4). The smallest size of the defect was 6x4x3 cm, while the largest one was 20x15 cm (Table 5).



**Table 2.** Sex

Sex	Amount	Percent
Male	5	55,6%
Female	4	44,4%

**Table 4.** Site of The Defects

Site of defect	Amount	Percent
Face	1	11,1%
Neck	1	11,1%
Cruris	4	44,4%
Pedis	3	33,3%

**Table 3.** Etiological Causes of Defect

Types	Amount	Percent
Burn	1	11,1%
Fracture	4	44,4%
Tumor	3	33,3%
Infections	1	11,1%

**Table 5.** Defects and Flap Characteristics

Base of Defects	Amount	Percent	Size	Flap Size	Pedicle
Bone	5	55,6%	Length 10-20 cm Width 5-13 cm	Length 10-20 cm Width 5-16 cm	8-12 cm
Soft tissue	1	11,1%	13x10 cm	12x22 cm	12 cm
Implant	1	11,1%	6x4x3 cm	9,5x5 cm	10 cm
Bone and plate	2	22,2%	Length 13-18 cm Width 8-13 cm	Length 15-20 cm Width 10 cm	15 cm

## DISCUSSION

In our study, trauma was the commonest cause of soft tissue defects (5 cases, 55,5%), 3 cases (33,3%) were tumor caused by osteosarcoma and teratoma, 1 case (11,1%) were caused by infection. The cruris was the commonest site (4 cases, 44, 4%), pedis were 3 cases (33,3%), while the face and neck have each 1 case (11,1%). Kuo and Jeng stated that most of their soft tissue defects were located in the lower extremities and caused by trauma<sup>10</sup>. Whereas Wienzig and Davis, series trauma reported in 48% and vascular insufficiency represented in 40% cases<sup>11</sup>. Kuo et al operated 28 free flaps and their defects at the lower limb<sup>10</sup>, while shieh et all operated 36 patients using ALTF in the head and neck<sup>12</sup>. Flap failure was reported in 1 case in our study due to vein compromise (Figure 2). Kuo et al reported failure rate 3%<sup>10</sup>,

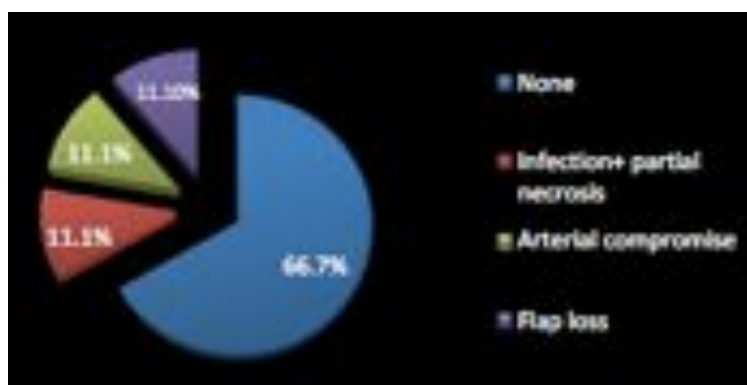
while Wei reported a total of 1,8 % total failure and 2,5 % partial failure. In this case the largest flap was 20x14 cm and the smallest flap was 9,5x5 cm. Kimata et al has done ALTF with flap size ranges from 4x7 cm to 8,5x22 cm<sup>13</sup>, while Koshima et al stated that their ALTF ranged in size from 8-25 cm in length and 4 to 18 cm in width.

In this study, ALTF has a long vascular pedicle ranging from 8 to 15 cm.

## CONCLUSION

Free ALTF is suitable for coverage of defects in many parts of the body. From our study, we can conclude several things from ALTF that can be summarized as follow : (1) In our hospital, we are quite familiar with ALTF even though the case is limited, (2) ALTF is used for reconstruction of various simple and





**Figure 2.** Percentage of Early Post-operative Complications.

complex soft tissue defects, for big and small defects with cavity (orbita), (3) The flap is commonly used for treatment of post traumatic lower limb with bone and implant as base of defects, (4) The donor site can be closed primarily or covered with split thickness skin graft, (5) ALTF in our study has a vascular pedicle ranging from 8 to 15 cm, and (6) The flap is often used to close a defects that cannot be closed by other department, such as orthopaedics, internal medicine, burn unit and ophthalmology department who underwent free fibular tissue transfer right after tumor excision (one out of four patient) there were no complications in five months follow up.

**Parintosa Atmodiwirjo, M.D.**

**Plastic Surgery Division**

Cipto Mangunkusumo General National Hospital  
Jalan Diponegoro.No.71, Gedung A, Lantai 4.

parintosaa@yahoo.com

## REFERENCES

1. Abdel khalek. AH., Allam. AM., Hendy.A.,Et All : Clinical evaluation of free anterolateral thigh flap in the reconstruction of major soft tissue defects in the leg and foot. *Plast.Reconstr. Surg.* , 2 :173-180, 2003
2. Smit JM., Zeebregts CJ., Acosta R., Werker PMN : Advancements in free flap monitoring in the last decade : a critical review. *Plas. Reconstr. Surg.*, 125 : 177, 2010
3. Saint-Cyr. M., Schaverien MV., Rohrich RJ : Perforator Flaps : history, controversies, physiology, anatomy and use in reconstruction. *Plas. Reconstr. Surg.* 123 : 132e, 2009
4. Ali RS., Langner RB., Rodriguez ED., Cheng MH : The Versatility of the anterolateral thigh flap. *Plast. Reconstr.surg.* 124 : 395e, 2009
5. Wei, FC and Mardini S : Flaps and reconstructive surgery.Saunders.-elseviers Inc. 2009
6. Wolff KD and Holzle F: Raising of microvascular flaps. A systematic Approach. Springer Berlin Heidelberg New York. 2005
7. Begue. T and Masquelet C : Anterolateral Thigh Chapter 22 in Encyclopedia of flaps. Torso, pelvis and lowe extremities. Grabbs Vol 3. Lippincott Williams and wilkins. 2009.
8. Mehrara BJ : Reconstruction of the cheeks chapter 37 in Grabbs&smith's Plastic surgery 6th ed. Lippincott Williams and wilkins. 2007.
9. Saint-Cyr. M., Schaverien MV., Rohrich RJ Et All : The extended anterolateral thigh Flap : Anatomical basis and clinical experience. *Plast. Reconstr. Surg.* 123 : 1245, 2009
10. Kuo Yr, Jeng SF et all : Free anterolateral thigh flap for extremity reconstruction : Clinical experience and functional assessment of donor site. *Plast. Reconstr.surg.* 107: 1766,2001
11. Weinzig n and Davies B.W: foot and ankle reconstruction using the radial forearm flap: a review of 25 cases. *Plast.reconstr.surg.* 102. 1999, 1998
12. Shieh SJ.,Chiu HY et all : Free anterolateral thigh flap for reconstruction of head and neck defects following cancer ablation. *Plast.recon.surg.*105:2349,2000
13. Kimata Y., Uchiyama K Et All: Anterolateral thigh flap donor site complications and morbidity. *Plast.reconstr.surg.*106:584,2000