

## THE EFFECT OF ESTROGEN AND OR CALCIUM- VITAMIN D<sub>3</sub> ON THE MANDIBULAR HEIGHT OF POST OVARIECTOMIZED WISTAR RATS

Henri D\*, Erwin\*, Jimmy G\*, Niniarty ZD\*\*, Dewi F\*\*, Angky S\*\*

\*Mahasiswa Fakultas Kedokteran Gigi  
\*\*Staf Pengajar Oral Biology  
Fakultas Kedokteran Gigi Universitas Indonesia

Henri D\*, Erwin\*, Jimmy G\*, Niniarty ZD\*\*, Dewi F\*\*, Angky S\*\*: The Effect of Estrogen And Or Calcium-Vitamin D<sub>3</sub> On The Mandibular Height of Post Ovariectomized Wistar Rats. Jurnal Kedokteran Gigi Universitas Indonesia 2003; 10 (Edisi Khusus):236-241

### Abstract

One of the major health problems in elderly women is osteoporosis post menopause. Dentists must be aware of the disease since its involvement on the jaw. Nowadays, there are a lot of researches on correlation of osteoporosis and mandible but only few concentrate on hormonal substitution therapy and/or Calcium-vitamin D<sub>3</sub> (Ca-vit D<sub>3</sub>). This research is to evaluate the effect of hormonal substitution therapy and/or Ca-vit D<sub>3</sub> on mandibular height. Forty five rats are used in this research and divided into nine groups: one control group, two ovariectomized (OVX) groups, two OVX groups treated with estrogen, two OVX groups treated with Ca-vit D<sub>3</sub>, two OVX groups treated with estrogen and Ca-vit D<sub>3</sub>. All of the rats except the control groups were ovariectomized as model for postmenopausal estrogen deficiency state. The treatment was done in two or four weeks. The animals were killed with cervical dislocation, the mandible were excised and soaked on Hydrogen Peroxide 10%. Then the mandible's heights on right buccal side were measured from the mandibular base to the alveolar crest. It is concluded that hormonal substitution therapy and combination of the hormonal substitution therapy and Ca-vit D<sub>3</sub> can maintain the normal mandibular height. Mandibular height of groups with therapy using Ca-vit D<sub>3</sub> have slightly lower means compared to control group but without significant difference statistically. The best therapy is combination of hormonal substitution therapy and Ca-vit D<sub>3</sub>.

Key Words: Menopause, Osteoporosis, Ovariectomy, Estrogen, Calcium, Vitamin D<sub>3</sub>, and Mandibular Height.

### Introduction.

One of the major health problems that take attention for most women, especially women over 60 years old, is osteoporosis because its increase in number and incidence of hip fracture. According to Mitchell and Stancel (2001), 20% of those who suffer hip fracture passed away 12 months after the

incidence.<sup>1</sup> The increase of bone resorption, which exceeds normal resorption rate without bone apposition, is common in estrogen deficiency state. This cause bone loss and decrease of bone density.<sup>2</sup> With aging, it is found that there is a decrease on cortical mandibular mass, but not on trabecular part.<sup>3</sup> Even though, still there are controversial

arguments on the relationship between mandible and other parts of body.<sup>4</sup>

The relationship on dentistry is quite clear that menopausal women often complain with her denture.<sup>5</sup> Excessive jaw resorption will cause instability of the denture. Implants are contraindicative because jaw can not give support for implants.<sup>6</sup> Osteopenia happens on periodontal tissues that can cause teeth mobility and avulsion.<sup>2, 7</sup> Even until today, there are a lot of researches on correlation of osteoporosis and mandible but only few concentrate on hormonal substitution therapy and/or Ca-vit D<sub>3</sub> on mandible. Research that can show the effect of hormonal substitution therapy and/or Ca-vit D<sub>3</sub> on bone is ovariectomy on rats. Bilateral ovariectomized rats act as models to perform menopausal state.<sup>8</sup> This research uses ovariectomized Wistar rats and evaluates the effect of ovariectomy and hormonal substitution therapy and/or Ca-vit D<sub>3</sub> on mandibular height.

## Materials and Methods

Forty-five, four months old, female Wistar rats, weighing between 154 - 258 g that have give birth at least once were used in this research. They were divided equally into one control group and eight experimental groups with two ovariectomy groups (OVX), two OVX groups treated with estrogen (EST), two OVX groups treated with Ca-vit D<sub>3</sub> (CD), two OVX groups treated with estrogen and Ca-vit D<sub>3</sub> (ECD). Under general anesthesia with diethyl eter, the mice underwent

ovariectomy except the control group. In each of the experimental groups, the mice were killed two and four weeks after operation. Estrogen preparations (estradiol hemihydrates 2 mg tablets: ESTROFEM, NOVO NORDISK) and Ca-vit D<sub>3</sub> preparations (Ca hydrogen phosphate dihydrate 500 mg and 133 IU cholecalciferol tablets: CAVIT-D<sub>3</sub>, MERCK) were dissolved in 10% Carboxy Methyl Cellulose and given per oral daily.

The mice were killed by cervical dislocation and their mandibles were removed and soaked in 10% H<sub>2</sub>O<sub>2</sub> solution for 2 days. After the bones were free from the soft tissues, the mandibular height was measured from the alveolar crest on buccal of the first Molar to inferior edge of the mandible using digital calipers.

One Way ANOVA were used to test for the difference between the groups; P-values of less than 0.05 were considered statistically significant.

## Results

Fig. 1 and Fig. 2 show changes in mandibular height of the control and treatment groups. The mandibular heights of all two weeks group's show no significant difference with the control groups. The OVX, EST, and ECD groups show slight decrease compared to control group. During four weeks observation time, significant difference was shown by ECD and control group. Only OVX and CD groups show lower values of mandible height.

Fig. 1. Mandibular height on two weeks observation

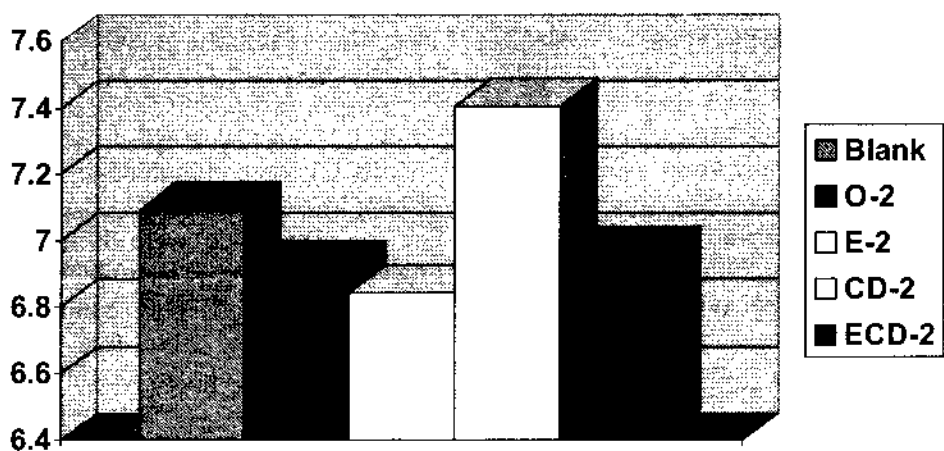



Fig. 2. Mandibular height on four weeks observation



Discussion

Osteoporosis is one of major problem faced by postmenopausal women because its high risk of bone fractures.<sup>9</sup> Osteoporosis happens when there is imbalance between the rate of bone formation and resorption. Postmenopausal estrogen deficiency state gives direct influences on dental treatment. The quality and quantity of alveolar bone should be considered in designing dentures. Specimens used in this research are wistar rats that had given birth to case ovariectomy procedure. Mandibular height was measured

on the buccal side of the first molar on two and four weeks after operation. Kawamoto (2002) observed that TRAP positive cells are abundantly found on buccal side of mesial root of first molar and estrogen deficiency state increases osteoclast formation within 14 days even though pre-osteoclast activity had begun 7 days after ovariectomy.<sup>10</sup> Hirai (1993) states a significant difference between the height of the mandible with the severity of osteoporosis and no specific changes on blood Ca and P level of osteoporotic

\*TRAP ( Tartrate -Resistant Acid Phosphatase ) is a specific marker for osteoclast

women.<sup>11</sup> Taguchi (1995) states that besides Bone Density Measurement (BMD), alveolar bone height is a reliable measure on diagnosing osteoporosis.<sup>12</sup>

The present result indicates that mandibular height was not change for all groups during two weeks after ovariectomy. Body can still maintain Ca homeostasis even though estrogen level has decreased. Blood estrogen level was not completely reduced after ovariectomy, but the decrease in estrogen level will be compensated. In postmenopausal women, blood estrogen level decrease as much 12 µg / 24 hours.<sup>13</sup> Estradiol level in ovariectomized rat was 6.5 pmol / liter and in normal rat as much 27.5 pmol / liter.<sup>14</sup> There are another source of estrogen other than ovaries which is the adrenal cortex. Besides that growth hormone, insulin, and thyroid are also having role in preventing fast bone loss.<sup>15</sup> In conclusion, short-term estrogen deficiency state is not the only factor that cause bone loss.

During 4 weeks period, the decrease in mandibular height can be observed. The effect of estrogen deficiency is the increase in osteoclast formation in 14 days.<sup>14</sup> Fujita states that the increase of TRAP positive cells and decrease in bone trabecular volume of ovariectomized Wistar rats were found four weeks after ovariectomy.<sup>16</sup> This research states that there is a decrease in mandibular height of the OVX 4 group compared to Blank even though it is not significant statistically. If the sample number increased or observation time lengthened, the difference would be more significant.

Hormonal Replacement Therapy (HRT) is a chosen therapy for eliminating the estrogen deficiency state.<sup>1, 17, 18</sup> Lippert states that estradiol preparation can be used as first choice for HRT in post menopausal women.<sup>15</sup> Estradiol is the most effective preparation for human and the most similar preparation to body's natural hormone. The side effect of estradiol is limited because it only induces few heart proteins.<sup>19</sup> Even though, still there are increase of the risk of stroke, venous thrombo-emboli, pancreatitis, endometriosis, and vagina, breast, endometrium, ovary cancer.<sup>1, 18</sup> The combination of estrogen and progesterone reduces the risk of those side effects.

Estrogen inhibits bone resorption process through its effect on osteoblast and osteoclast. It is known that osteoblast and osteoclast have estrogen receptors. Estrogen stimulates differentiation of osteoblast through osteocalcin, osteopontin, osteonectin, and alkaline phosphatase.<sup>1</sup> Interleukin-1,6,11; Transforming Growth Factor-β, Macrophages-Colony Stimulating Factor, leukocyte inhibiting factor, and stem cell factor are signals form osteoblast which activate osteoclast.<sup>17</sup> Estrogen can inhibit osteoclast activation through inhibition of those cytokines and increasing m-RNA expression for Insulin-like Growth Factor-1 and TGF-β.<sup>16</sup> Estrogen can also give direct effect on osteoclast with acceleration of osteoclast apoptosis.<sup>1</sup> This research proves that on EST 2 and EST 4 groups show no significant difference compared to control group. In conclusion, administration of estradiol as hormone replacement therapy is effective to maintain mandibular height.

The main role of vitamin D is the regulation of calcium homeostasis so that vitamin D<sub>3</sub> has various receptors on various organs, especially in the intestine and bone. Vitamin D<sub>3</sub> plays a role on increasing calcium absorption in the intestine. On bone, vitamin D<sub>3</sub> reduces bone remodeling process and increases bone mass through increasing osteocalcin level which increase bone mass and density through osteoblast recruitment.<sup>14</sup> Combination of vitamin D<sub>3</sub> and Ca is very useful for post-menopausal women. Calcium intake as much 1500 mg/day added with vitamin D<sub>3</sub> as much 400 IU is a suggested dose for post menopause women.<sup>13</sup> Combination of vitamin D<sub>3</sub> and Ca can decrease serum Parathyroid Hormone (PTH) level.<sup>9</sup> The decrease of serum PTH level decreases bone resorption activity, so that there is a reduce of bone loss on post menopausal women. If serum calcium level is high, vitamin D<sub>3</sub> will much greater hydroxylated into 24, 25 (OH)<sub>2</sub> D<sub>3</sub> (secalciferol) which stimulates bone formation.<sup>20</sup> On the other hand, high concentration of calcium-vitamin D<sub>3</sub> can stimulate bone resorption through inhibition of bone collagen synthesis.<sup>14</sup> Calcium-vitamin D<sub>3</sub> therapy as single therapy is quite effective on maintaining mandibular height. Even

though, estrogen's role is quite significant on calcium metabolism. Estrogen administration enhances the calcium absorption rate in intestine and calcium retention in kidney.<sup>21</sup> The present study gives similar result that there is no significant difference of CD 2 group compared to control group.

Combination between estrogen, calcium, and vitamin D<sub>3</sub> is a more effective therapy to prevent excessive bone resorption. Loose-Mitchell states that enough calcium and vitamin D<sub>3</sub> intake on daily foods can increase the success of HRT.<sup>1</sup> Combination therapy gives higher rate of success compared to single therapy because of its synergistic effect. Longer period of therapy may eventually increase mandibular height. The similar result reported by Civitelli (2002) which state there is an increase of alveolar bone height after estrogen, calcium, and vitamin D<sub>3</sub> administration for three years on post menopausal women.<sup>22</sup> In conclusion, combination therapy in long period is the most effective therapy on maintaining the mandibular height.

## References

1. Loose-Mitchell DS, Stancel GM. Estrogen and Progestin in: Hardman J, Limbird LE, Molinoff PB, Ruddorn RW, Gilman AG. Goodman dan Gilman's: *The Pharmacological Basis of Therapeutics* 10<sup>th</sup> Ed. New York: Mc Graw-Hill. 2001 : 1597-1629
2. Budi Santoso R. *Metabolik Endokrinologi Rongga Mulut*. Buku Ajar Praktis. UI Press. 1992 : 40
3. Kribbs PJ, Chesnut CH, Ott SM, Kilcoyne RF. Relationships between Mandibular and Skeletal Bone in a Population of Normal Women. *J Prosthet Dent* 1990 ; 63 : 86-89
4. Speroff L. The Menopause: a Signal for the Future in: Lobo RA (Ed.) *Treatment of the Post-Menopausal Women: Basic and Clinical Aspect*. New York: Raven Press. 1994 : 1-10
5. Ruslan, Boedi Oetomo. Mewaspadai Osteoporosis dalam Melakukan Perawatan Gigi dan Mulut. *Jurnal Kedokteran Gigi Universitas Indonesia*. 1997; 4 (Edisi Khusus KPPIKG XI) : 745-750
6. Perel ML. *Dental Implantology and Prothesis*. Philadelphia: Lippincott. 1997 : 25
7. Chestnut CH. *Osteoporosis: Principles of Geriatric Medicinal and Gerodontology* 2<sup>nd</sup> Ed. Mc Graw-Hill Inc. USA. 1990 : 777-81
8. Tanaka S, Shimizu M, Debari K, Furuya R, Kawawa T, Sasaki T. Acute Effects of Ovariectomy on Wound Healing of Alveolar Bone After Maxillary Molar Extraction in Aged Rats. *Anat Rec* 2001; 262 : 203-212
9. Von Wowern N. General and Oral Aspects of Osteoporosis: a Review. *Clin Oral Invest* 2001; 5 : 71-82
10. Kawamoto S, Ejiri S, Nagaoka E, Ozawa H. Effects of Oestrogen Deficiency on Osteoclastogenesis in the Rat Periodontium. *Archives of Oral Biology* 2002, 47 : 67-73
11. Hirai T, Ishijima T, Hashikawa Y, Yajima T. Osteoporosis and Reduction of Residual Ridge in Edentulous Patients. *J Prosthet Dent* 1993; 69 : 49-56
12. Taguchi A, Tanimoto K, Sueti K, Otani K, Wada T. Oral Signs as Indicators of Possible Osteoporosis in Elderly Women. *Oral Surg Oral Med Oral Pathol Oral Radiol Endod* 1995; 80 : 612-616
13. Golfien A, Mimroe SE. Ovaries in: Greenspan FS, Strewler GJ. *Basic and Clinical Endocrinology* 5<sup>th</sup> Ed. Philadelphia: Appleton and Lange 1997 : 434-476
14. Sims NA, Morris HA, Moor RJ, Durbridge TC. Increased Bone Resorption Precedes Increased Bone Formation in the Ovariectomized Rat. *Calcif Tissue Int* 1996; 59 : 121-127
15. Mundy GR, Martin TJ *Physiology and Pharmacology of the Bone*. Berlin: Springer-Verlag. 1993 : 299-322
16. Fujita T, Kawata T, Tokimasa C, Tanne K. Influence of Oestrogen and Androgen on Modelling of the Mandibular Condylar Bone in Ovariectomized and Orchiectomized Growing Mice. *Archives of Oral Biology* 2001; 46 : 57-65
17. Djokomoeljanto R. Patofisiologi dan Terapi Osteoporosis. *Farmacia* Ed. Dec 2002 ; 66-72
18. Parfitt K. *Martindale: The Complete Drug Reference* 32<sup>nd</sup> Ed. : Pharmaceutical Press. 1999 : 1434-1438
19. Lippert TH, Seeger H, Mueck AO. Postmenopausal Estrogen Therapy:

- Pharmacological Treatment or Substitution of the Missing Hormone? *Dtsch med Wschr* 1999; 124 : 1245-1248
20. Bilke DD. Agents that Affect Bone Mineral Homeostasis in: Katzung BG. *Basic and Clinical Pharmacology* 7<sup>th</sup> Ed. Connecticut: Prentice Hall International. 1998 : 706-721
  21. Heshmati HM, Khosla S, Simons SP, O'Falton WM, Melton J, Riggs BL. Role of Low Levels of Endogenous Estrogen in Regulation of Bone Resorption in Late Postmenopausal Women. *J Bone Miner Res* 2002;17 : 172-178
  22. Civitelli R, Pilgram TK, Dotson M, Lewandowski N, Villareal RA, Crothers NY, Hauser J, Cohen S, Hildebolt CF. Alveolar and Postcranial Bone Density in Postmenopausal Women Receiving Hormone/Estrogen Replacement Therapy. *Arch Intern Med*. 2002; 162 : 1409-1415