



## Clinical cardiac manifestations in patients with coronavirus disease 2019 (COVID-19)

Hafizha Herman, Putrika PR Gharini, Lucia Kris Dinarti\*

Department of Cardiology and Vascular Medicine, Faculty of Medicine, Public Health and Nursing, Universitas Gadjah Mada, Yogyakarta, Indonesia

### ABSTRACT

Submitted : 2020-04-30  
Accepted : 2020-06-04

The pandemic of coronavirus disease 2019 (COVID-19) caused by the severe acute respiratory syndrome coronavirus 2 (SARS-CoV-2) has infected more than 2 million people worldwide with case fatality rates between 3-15%. The pathophysiology of this newly emerging disease in affecting cardiovascular system is poorly understood. This review aimed to understand from various retrospective studies and case reports that have been published and updated during the pandemic of COVID-19 related to the underlying mechanism and cardiovascular interaction with coronavirus. A literature search was done with Google search, PubMed, European Society of Cardiology (ESC) and Journal of American Medical Association (JAMA) network since the early days of COVID-19 pandemic. Clinical presentation may be asymptomatic or the severe cases will have acute respiratory distress syndrome (ARDS). Protein spikes of SARS-CoV-2 virus use the angiotensin-converting enzyme 2 (ACE2) as viral entry to host cells. Due to the upregulation of ACE2, people with any pre-existing cardiac diseases are more vulnerable to the infection and more likely to have a severe condition of COVID-19 infection with a higher risk of mortality. On the other hand, ACE2 has protective effects against myocardial inflammation and lung injuries. Several cases of COVID-19 infection may have cardiac manifestations as a chief complaint or acute cardiac injury as the complication. Recent case reports show that acute cardiac injury, myocarditis, cardiogenic shock, thromboembolism, and arrhythmias could be the complications of COVID-19 even without history or risk factors of cardiovascular disease. There are several hypotheses related to the mechanism of acute cardiac injury in COVID-19 patients, including damage through ACE2 receptors, hypoxia, cardiac microvascular damage, and inflammatory response. COVID-19 infection can cause many interactions in the cardiovascular system, whether the patients already had chronic heart disease or not. Considering the lack of evidence of the RAS inhibitor in COVID-19, the use of ACE inhibitor/ARB should be continued unless contraindicated and may be beneficial in patients with hypertension, heart failure and diabetes mellitus. Early recognition of cardiac manifestations from COVID-19 infections will be the key to prevent short and long term cardiac adverse events.

### ABSTRAK

Pandemi penyakit *coronavirus disease 2019*(COVID-19) yang disebabkan oleh *severe Acute respiratory syndrome coronavirus 2*(SARS-CoV-2) telah menginfeksi lebih dari 2 juta orang di seluruh dunia dengan tingkat fatalitas antara 3-15%. Pemahaman terhadap patofisiologi penyakit baru ini terhadap sistem kardiovaskular masih kurang. Tinjauan pustaka ini bertujuan untuk memahamimekanisme yang mendasari dan interaksi kardiovaskular dengan virus corona dari berbagai studi retrospektif dan laporan kasus yang terbit pada masa pandemik COVID-19 Pencarian pustaka menggunakan Google Search, PubMed, *European Society of Cardiology* (ESC), dan jejaring *Journal of American Medical Association* (JAMA) dimulai sejak awal masa pandemi COVID-19. Presentasi klinis dapat berupa kasus asimtomatik atau sampai berat yang memiliki sindrom gangguan pernapasan akut (ARDS). Protein permukaan S SARS-CoV-2 menggunakan reseptor enzim pengkonversi angiotensin 2 (ACE2)

### Keywords:

ACE inhibitor;  
acute cardiac injury;  
cardiogenic shock;  
coronavirus;  
myocarditis;

sebagai pintu masuk ke sel inang. Karena terjadi peningkatan reseptor ACE2 pada pasien dengan riwayat penyakit jantung sehingga lebih rentan terinfeksi dan lebih memiliki risiko keparahan sampai kematian lebih tinggi bila terinfeksi COVID-19. Di sisi lain, reseptor ACE2 memiliki efek protektif terhadap peradangan miokard dan cedera paru. Beberapa kasus infeksi COVID-19 mungkin memiliki manifestasi jantung sebagai keluhan utama atau cedera jantung akut sebagai komplikasi. Laporan kasus terbaru menunjukkan bahwa cedera jantung akut, miokarditis, syok kardiogenik, tromboemboli, dan aritmia bisa menjadi komplikasi pada pasien COVID-19 bahkan pada pasien tanpa riwayat atau faktor risiko penyakit kardiovaskular. Ada beberapa hipotesis yang terkait dengan mekanisme cedera jantung akut pada pasien COVID-19, antara lain kerusakan melalui reseptor ACE2, hipoksia, kerusakan mikrovaskuler jantung, dan respon inflamasi. COVID-19 dapat menyebabkan interaksi dengan sistem kardiovaskular baik pada pasien yang memiliki riwayat penyakit kardiovaskular sebelumnya maupun tidak. Mengingat kurangnya bukti dari inhibitor RAS di COVID-19, penggunaan *angiotensin converting enzyme inhibitor* (ACEi)/*angiotensin receptor blocker* (ARB) harus dilanjutkan kecuali terdapat kontraindikasi dan mungkin bermanfaat pada pasien dengan hipertensi, gagal jantung dan diabetes melitus. Deteksi dini manifestasi jantung dari infeksi COVID-19 menjadi kunci mencegah efek samping jantung jangka pendek dan panjang.

## INTRODUCTION

The outbreak of acute respiratory tract infections started since December 2019 in Wuhan, Hubei Province in China caused by the 2019-novel coronavirus (2019-nCoV) is still a global health problem.<sup>1</sup> This infectious disease which is now referred as coronavirus disease-2019 (COVID-19) is caused by the severe acute respiratory syndrome coronavirus 2 (SARS-CoV-2).<sup>2</sup> On the 11<sup>th</sup> of March 2020, the World Health Organization (WHO) declared COVID-19 as a pandemic with the number of cases globally already exceeding more than 5,000,000 cases and mortality rates exceeding 350,000 cases. The number of cases in Indonesia has exceeded 25,000 confirmed cases and mortality rates of more than 1500 cases at the end of May 2020 while the number of cases continues to increase every day.<sup>3</sup>

Coronavirus infections in humans are generally relatively mild, but the epidemic of the previous beta coronaviruses, severe acute respiratory syndrome coronavirus (SARS-CoV) and Middle East respiratory syndrome coronavirus (MERS-CoV) caused more than 10,000 cumulative cases in the last 2 decades with case fatality rates (CFR) of 10% for SARS-CoV and 37% for MERS-CoV.<sup>4</sup> Overall the total case fatality rate (CFR) in China reached 2.3%, with

80% of patients infected with COVID-19 experiencing symptoms of mild and cured without intensive medical intervention. However, some case reports reported morbidity and mortality rates were significantly increased at the age above 70 years (14.8%) and for patients with comorbidities such as hypertension (6%), diabetes mellitus (7.3%) and cardiovascular diseases (10.5%). This number is higher than that of the average CFR on the population without any comorbidity.<sup>5</sup>

Clinical manifestations in COVID-19 infections are generally dominated by pulmonary symptoms, but some patients experience severe cardiovascular damage. Cardiovascular comorbidity can also increase mortality.<sup>6</sup> Previous literature review of extra-pulmonary complications related to influenza infections including SARS-CoV showed that there is a clinical entity with viral myocarditis, cardiovascular events, with increases of hospitalization and deaths during epidemic periods.<sup>7</sup> Experience from emergency visits in New York City estimates there was also an increase in cardiovascular mortality during seasonal influenza infection.<sup>8</sup>

Acute and chronic cardiovascular complications of pneumonia often occurring and are the result of multiple mechanisms among other factors

including relative ischemia, systemic inflammation and pathogen-related damages. This COVID-19 outbreak underscores our needs to develop a deeper understanding of the implications of viral infections on both the short and long-term cardiovascular system.<sup>9</sup> The pathophysiology of this newly emerging disease in affecting cardiovascular system is poorly understood. This review aimed to give an understanding from various retrospective studies and case reports that have been published and updated during the pandemic of COVID-19 related to the underlying mechanism and cardiovascular interaction with coronavirus. Furthermore, we want to look for the short-term and long-term effect of this viral infection to cardiac complication.

## MATERIALS AND METHODS

A literature search was done with Google search, PubMed, European

Society of Cardiology (ESC) and Journal of American Medical Association (JAMA) network since the early days of COVID-19 pandemic. Search terms of ‘COVID-19’, ‘coronavirus’, ‘SARS-CoV-2’, ‘acute cardiac injury’, ‘ACE inhibitor’, ‘ACE2 receptor’, ‘myocarditis’, ‘cardiac manifestation’, ‘arrhythmia’, and ‘cardiogenic shock’ was used in combination for literature searching. Other than that, we also went through the article’s reference from the relevant literature. The article published in other than English language was excluded from this review. We reviewed articles consist of retrospective study, cohort, case report/series from different part of the world that has been affected with COVID-19. The population of the studies consist of patients that treated in-hospital from mild to severe cases.

## RESULT

### Pathogenesis of COVID-19

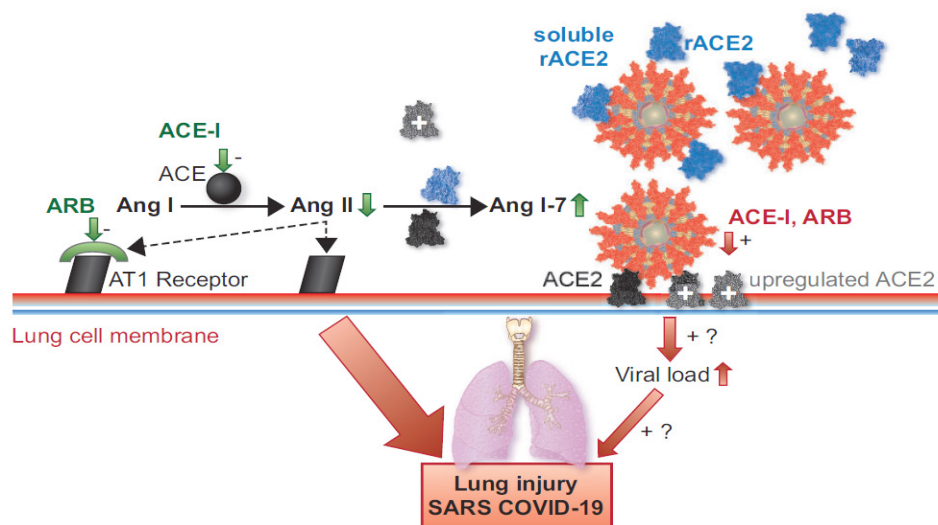


FIGURE 1. Schematic figure describing the role of Angiotensin-Converting Enzyme (ACE) in Coronavirus Disease 2019 (COVID-19) infection related to viral infection into the lungs. The ACE2 act as the entry receptors of the virus to the host cell, and its number may be upregulated due to the chronic use of Angiotensin-converting enzyme inhibitor (ACEi) or Angiotensin Receptor Blockers (ARB). This condition may cause the increased viral load. On the other hand, the high level of ACE2 and the use of ACEi/ARB may have some protective effects by increased production of Ang 1-7 that has vasodilatory and anti-inflammatory effects, preventing further lung injury and cardiac damage (16, with permission from Oxford University Press Journal)

Coronavirus (CoV) is a family of single-stranded RNA viruses that can infect both animals and humans, causing respiratory diseases, and problems with gastrointestinal tract, kidneys, liver and nerves.<sup>10</sup> Coronavirus is a corona- $\beta$  enveloped non-segmented positive-sense single-stranded RNA part of the family Coronaviridae and order Nidovirales.<sup>4</sup> Transmission methods that have been researched indicate that the main transmission line is through respiratory droplets either via airborne or direct-contact. Recent case report shows that there is a possibility of viruses can be transmitted through the feces-oral route as well as the transmission to fetus in pregnant women.<sup>10</sup> SARS-CoV-2 compared to SARS-CoV and MERS-CoV has a faster transmission speed with a longer incubation period of 2-14 (mean 5.2) days. The peak season is the same as SARS-CoV in the winter between December and January, while MERS-CoV typically occurs in the summer between May-July.<sup>11</sup>

The structure of the SARS-CoV-2 virus, measuring between 26-32 kilobases (kb), is one of the largest viral genomes. The virion has a nucleocapsid consisting of a genomic RNA and a phosphorylated nucleocapsid protein (N), which is located in phospholipid bilayered membranes. Membrane phospholipids are coated with two different types of spike protein structure namely trimmer glycoprotein (S) and hemagglutinin-esterase (HE). Membrane proteins (M) and envelope (E) are located between the S proteins in the virus wrapper.<sup>12</sup> There are many similarities found from the 3-dimensional computer model that shows the protein spike structure between SARS-CoV-2 with SARS-CoV is almost identical to that of the receptor areas that maintain van der Waals forces.<sup>13</sup>

The protein spike has a strong binding affinity towards angiotensin-converting enzyme 2 (ACE2) receptor in humans based on the analysis of

biochemical and structural interaction. ACE2 is an integral glycoprotein of the type 1 cell membrane which is expressed and active in many human tissues. The highest expression of ACE2 is observed in the lungs, endothelium, intestines, kidneys and heart. The lungs are more susceptible to infection than other target organs due to the large area of the lung surface and 83% of the cells expressing ACE2 are alveoli cell epithelium type 2.<sup>13</sup>

ACE2 is known to be a functional receptor for SARS-CoV-2 and SARS-CoV viruses to initiate the process of infection by making a bond between the protein spike in the viruses with ACE2 receptors.<sup>6</sup> As mentioned before, SARS-CoV-2 has similarities with the previous SARS-CoV virus, and this similarity is critical from previous research on SARS-CoV. An autopsy on animal models and humans showed SARS-CoV suppresses ACE2 pathways in the myocardium and lungs, thereby causing myocardial inflammation, pulmonary edema and acute respiratory failure.<sup>9</sup> Injecting SARS-CoV spikes into mice models demonstrated the critical steps of viral entry into the host cells because the RAAS system was blocked by attenuated ACE2 expression leading to lung injury. It shows that ACE2 is not only acting as an entry receptor but also protects against lung injury.<sup>13</sup>

The ACE2 receptors have an important role in the cardiovascular and immune systems. Angiotensin II in the renin-angiotensin system (RAS) is the main substrate for the ACE2 receptors.<sup>14</sup> The ACE2 receptors catalyze the changes of angiotensin II to angiotensin 1-7, which serve as vasodilators and create the effect of protection to the cardiovascular system. In the study with animal models, there is a link to the introduction of ACE inhibitor (ACEi) and angiotensin receptors blocker (ARB) with increased expression and activity of the ACE2 in various organs including the heart. The secretion of ACE2 in urine is

also increased in hypertensive patients treated with ARB, which signifies an increase in the number of ACE2 receptors in a patient's cells with ARB therapy.<sup>15,16</sup>

### **COVID-19 in patients with cardiovascular disease**

Respiratory symptoms appear to be heavier in patients with cardiovascular disease, where hypotheses to date associate this respiratory distress or dyspnea with increased ACE2 excretion compared to healthy individuals. The number of ACE2 receptors can be increased by the use of ACEi/ARB.<sup>6</sup> The evidence related to ACEi and ARB therapy in patients with or without pre-existing cardiac conditions in the COVID-19 pandemic period is still debatable. There are two main hypotheses regarding the inhibition of the RAS.<sup>17</sup>

The first possible mechanism shows the use of RAS inhibitors will increase the ACE2 level, which is the binding site for SARS-CoV-2. On the other hand, the other possibilities show that the viral infection will cause lung injury and decreased expression of ACE2. The use of ACE inhibitors will diminish the production of angiotensin II, while ARB will block the action of angiotensin II and AT1 receptors, which leads to enhanced generation of angiotensin 1-7, which attenuate inflammation and fibrosis and play protective roles in the cardiovascular system.<sup>17</sup>

Meanwhile, the upregulation of ACE2 by RAS inhibitor will increase the anti-inflammatory and anti-oxidative effects which may be beneficial to prevent lung injury. Professional societies of cardiovascular disease and hypertension in Europe and America recommend to continue the use of ACE inhibitor/ARB in COVID-19 patients unless clinically indicated but they do not suggest initiation of the drugs unless patients have hypertension, heart failure or diabetes mellitus.<sup>18</sup> Abrupt

withdrawal from these drugs may cause clinical instability and adverse health outcome in patients with pre-existing cardiovascular diseases.<sup>19</sup>

Experiments related to ACE2 expression in the human heart showed that there was low expression of ACE2 in cardiomyocytes compared to the intestines, testis and kidneys, although ACE2 was highly expressed in pericytes that spread outside the endothelial cells of capillary and venules. The SARS-CoV-2 infection may attack the pericytes and cause endothelial cell dysfunction which may explain the microcirculation disorders in the human heart.<sup>20</sup>

There are some speculation about favorable conditions of pulmonary hypertension (PH) in COVID-19 infection. Reports from the researchers and clinicians of PH found that only 13 patients with PH were infected with COVID-19 and only 1 patient died. There is a biological plausibility that this may be because of a PH specific mediation such as endothelin receptor antagonist, phosphodiesterase-5 (PDE-5), nitrite oxide and prostacyclin which had protective effects. Endothelin receptor antagonists may inhibit angiotensin II, and in the process, the layers of the pulmonary endothelial cells show microvascular inflammation of endothelium hypothetically may interrupt the cytokine sudden releases syndrome, now known as the 'cytokine storm'.<sup>21</sup>

### **Cardiac manifestations**

Cardiovascular complications in an influenza viral outbreak can generally be categorized as myocardial, acute myocardial infarction, and cardiac failure. As observed in the previous influenza season, it can contribute to increased mortality in patients over 65 years of age, especially in patients with coronary heart disease.<sup>8</sup> When compared to SARS-CoV infection which

has cardiac manifestations such as an increase of sympathetic activities, cardiac arrest and sub-clinical diastolic disorder, and MERS-CoV with acute myocardial manifestations and acute

heart failure, a recent study of cardiac manifestations in patients COVID-19 shows the manifestation of cardiac acute cardiac injury, shock and arrhythmia.<sup>9</sup>

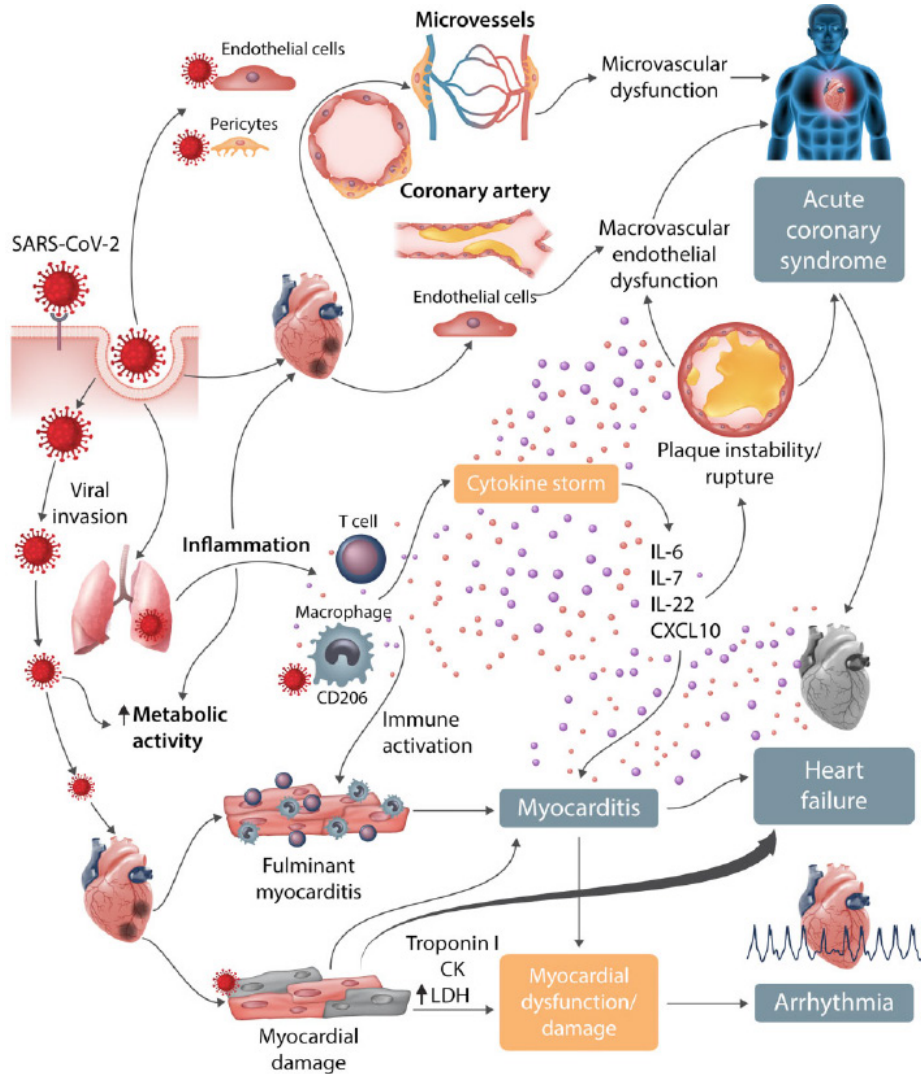


FIGURE 2. Cardiovascular manifestation and hypothetical mechanism in SARS-CoV-2 infection. Started with the penetration of coronavirus to host cells including type 2 pneumocytes, macrophages, endothelial cells, pericytes, and cardiac myocytes leads to severe microvascular and macrovascular dysfunction. In respiratory tract infection, SARS-CoV-2 infection could lead to 'cytokine storm' which is possible to activate T cells and macrophage then infiltrate myocardium resulting in severe cardiac damage such as myocarditis, plaque instability/rupture. That mechanism may cause the acute coronary syndrome, heart failure and arrhythmia (28, with permission from Oxford University Press Journal).

COVID-19 patients with cardiovascular comorbidities are more likely to develop acute cardiac injury and heart failure. Death from cardiac complications are not only found in patients with cardiovascular diseases but also patients without any previous cardiovascular conditions. This signifies that the high risk of death caused by cardiac complications has not been said solely due to the pre-existing conditions of cardiovascular disease. Although cardiovascular disease characteristics such as chronic hypertension are more commonly found in deceased patients.<sup>22</sup> Patients with underlying cardiovascular and metabolic diseases also have a 2-fold incidence in cases requiring intensive care. Meanwhile the patient with acute cardiac injury has a 13-fold incidence in the case of intensive treatment.<sup>23</sup>

The severity of primary respiratory syndrome also increases the risk of complications in patients with a history of cardiovascular diseases.<sup>9</sup> Sometimes, patients have presented with chest pain complaints such as typical angina and palpitations without any respiratory symptoms but are confirmed with COVID-19. Among the patients without the previous cardiovascular disease, there are patients who experienced significant heart failure, with increased heart enzymes troponin I or cardiac arrest during hospital treatment.<sup>6</sup>

Liu *et al.*,<sup>1</sup> reported that COVID-19 patients with cardiac manifestations (58.5%) have lower baseline value of lymphocytes,  $(0.99 \pm 0.43) \times 10^6/L$ , throat swab showing more than one positive nucleic acid (50%), and more oxygen supplementation required (79%) when compared to the group without cardiac manifestations. However, multivariate analysis using logistic regression model suggests that cardiovascular manifestations are not an independent predictor of hospital adverse events. Sudden cardiac arrest can occur as a result of prolonged sedentary hypoxia

causing myocardial suppression .

Infection of COVID-19 may be divided into 3 stages, consisting of mild, moderate and severe stages. The early infection is associated with mild and non-specific systemic symptoms, and prognosis and recovery are excellent. Some patients may progress to the moderate stage with pulmonary involvement with or without hypoxia. A minority of patients will develop the severe stage with systemic hyper-inflammation which manifests as an extra-pulmonary syndrome. In this stage, systemic hyper-inflammation may increase cardiac biomarkers such as Troponin and N-terminal pro-B-type natriuretic peptide (NT-proBNP) as the signs of acute cardiac injury or myocarditis.<sup>24</sup>

#### *Acute cardiac injury*

Acute cardiac injury related to viral infection was reported in 5 of 41 patients in China treated with COVID-19, and had high sensitive-cardiac troponin I (HS-cTnI) value increased over 99 normal value percentiles.<sup>4</sup> Research on 41 medical officers in China with an average age of 39 years old infected with COVID-19 found they experienced acute cardiac injury characterized by the increase of HS-cTnI above the value of 99 percentile, or new abnormalities in electrocardiogram and echocardiography during the period of COVID-19 infections.<sup>1</sup> A total of 23% of 52 patients with COVID-19 who were critically ill had also experienced acute cardiac injury.<sup>25</sup> Meanwhile, Shi *et al.*<sup>26</sup> reported that patients with an underlying cardiac disease were more likely to develop an acute cardiac injury, and it is significantly and clinically associated with higher risk of in-hospital mortality.

There are several hypotheses related to the mechanism of acute cardiac injury in patients with Coronavirus infection, including damage of ACE2 receptors, hypoxia, cardiac microvascular

damage, and inflammatory response. Increased affinity to ACE2 receptors and decreased expression count from ACE2 is considered the source of the occurrence of dysregulation in the RAS system. Severe damage to the state of the lung leads to oxidative stress that causes an intra-cell acidosis and mitochondrial damage. In conditions like the viral myocarditis, a microvascular breakdown occurs which causes a disruption of the fusions into myocardial. In the condition of the systemic inflammatory response is the occurrence of the 'cytokine storm' and disruption of the immune system that causes uncontrolled inflammation.<sup>6</sup>

Pathological changes in myocardial tissue can occur due to viral replication directly in myocardial or indirect through the systemic inflammatory response as a response to breath failure or an unexpected immune response due to viral infections. Inflammation of the myocardial and symptoms associated with the suppression of the ACE2 system can lead to myocardial dysfunction and cardiac complications. Consensus experts in China indicate immediate damage to the cardiac structure occurs more often in neonates, whereas in adults the immunogenic damage is a major factor.<sup>27</sup>

The reversibility condition of the cardiac structure and function without significant decline after the cure of the COVID-19 virus makes it possible that besides the mechanisms of viral replication in the myocardium, the immune response or 'cytokine storm' can also be an important mechanism. The 'cytokine storm' is a phenomenon involving the production of a wide range of cytokines in massive and rapid levels of body fluids after infected with a microorganism. It is an important cause of acute respiratory failure and multiple organ dysfunction. Interestingly, these cytokine storms can improve vascular wall permeability and myocardial edema, which explains the occurrence of

thickening of the heart walls in patients with myocarditis and it can potentially destabilize atherosclerotic plaques that may cause acute coronary syndrome (ACS).<sup>27,28</sup> There's lack of study regarding the incidence of ACS in COVID-19, but in viral infection, we should consider the myocardial infarction type 2, because of mismatch perfusion and demand in the myocardium, was the most common subtype of ACS.<sup>28,29</sup>

### *Myocarditis*

A case report from Sichuan, China described the case of a male patient aged 37 years with chest pain and tightness complaints since three days before admission accompanied by diarrhea, with a clinical presentation of hypotension. The supporting examination obtained cardiac enlargement and an ECG image leading to acute myocardial infarction of ST-segment (IMA-EST) inferiorly, supported by an increase in heart enzymes Troponin T more than 10,000 ng/L and NT Pro BNP 21.025 ng/L. Echocardiography test showed decreased fraction ejection (27%) and minimal pericardial effusion. A CT-scan coronary emergence examination was conducted and obtained normal coronary arteries results. After the result of the SARS-CoV-2 virus acid test was positive, the patient was then diagnosed as fulminant myocarditis with cardiogenic shock caused by COVID-19. After therapy with early glucocorticoids and human immunoglobulin the patient improved, and the evaluation of the heart dimensions returned to normal.<sup>30</sup> The wide QRS, atrioventricular block, tachycardia or ventricular fibrillation raises the risk of death in the hospital in patients with myocarditis.<sup>29</sup>

Examination of anatomical pathology in cardiac cells in patients aged 50 years in China with the ARDS and sudden cardiac death, only found slightly infiltrated mononuclear inflammatory



cells without any substantial myocardial tissue damage. Meanwhile from lung cell biopsies, there is desquamation of pneumocytes, the formation of hyaline membranes and pulmonary edema that supported the image of ARDS.<sup>31</sup> These results indicate the possibility that COVID-19 might not directly impair the heart.<sup>26</sup>

Sala *et al.*,<sup>32</sup> reported the case of 43 year old woman in Italy, who presented with chest pain and dyspnea. Her chest x-ray documented subtle bilateral opacities, and she was confirmed with SARS-CoV-2 positivity. The first clinical suspicion from ECG, cardiac biomarker and echocardiography was myocarditis. But, the dynamic 3D volume-rendering reconstruction of Cardiac CT-Scan demonstrated hypokinesia at the basal and mid-segment of the left ventricle with normal apical contraction suggesting a reverse Tako-Tsubo Syndrome (TTS). Then, the endomyocardial biopsy found an absence of viral infiltration in myocardium with diffuse T-lymphocytic inflammatory infiltrates. The final diagnosis was acute virus-negative lymphocytic myocarditis associated with SARS-CoV-2 respiratory infection.

Myocarditis is established with the gold standard of biopsy, immunology, or immunochemical examinations. The diagnosis of myocarditis has some challenges because the initial clinical presentation that appears more often leads to a typical chest pain of angina or acute heart failure. Supporting examinations such as cardiac magnetic resonance imaging (CMR) can be performed to help direct the diagnosis of clinically myocarditis suspicion.<sup>33</sup>

### *Cardiogenic shock*

A case report from the UK mentions a female patient case, 47 years with a major complaint of fever, shortness of breath and chest pain, without a history of previous cardiovascular risk factors.

Clinical symptoms with were unstable hemodynamics hypotension and tachycardia. ECG indicated the presence of ST elevation in the inferior-lateral, chest X-rays showing mild pulmonary edema. The patient once performed angiography three years earlier with normal coronary artery. Echocardiography indicated the presence of medium-pericardial effusion. She was hospitalized in the intensive cardiac care ward. Throat swab results confirmed the COVID-19 diagnosis. During the clinical treatment of the patient she deteriorated, and echocardiography evaluation showed a circumferential 2-cm pericardial effusion with cardiac tamponade. Finally, in the emergency treatment, there were serohemorrhagic fluid and negative test results for COVID-19.<sup>34</sup>

During the COVID-19 pandemic, the Chinese used the criteria of expert consensus to diagnose fulminated myocarditis. Fulminant myocarditis is a clinical diagnosis of myocardial inflammatory disease, accompanied by severe hemodynamic rapid deterioration. Accompanying signs and symptoms include sudden attacks, a clear history of viral infections, rapid and severe hemodynamic dysfunction, myocardial injury and a decrease in diffuse ventricular wall kinetics.<sup>35</sup>

### *Arrhythmia*

As previously mentioned above, viral infection can cause inflammation of myocardium, metabolic dysfunction and activation of sympathetic nervous system, that one of combination of this risk could precipitate an arrhythmia.<sup>29</sup> In critical ill patient, electrolyte imbalances can occur especially in a patient with cardiovascular comorbidity and may precipitate arrhythmia. One of the common electrolyte imbalance was hypokalemia. Hypokalemia caused by the effect of RAA system to retain water and sodium while excreted potassium.

Moreover, in SARS-CoV-2 infection, the ACE2 receptor function was altered and some patients may develop diarrhea as complication making the risk of hypokalemia even higher.<sup>35,36</sup>

Some drugs have been widely used in clinical practice as the trial for COVID-19 therapy but some of the drugs have been stated to possibly cause arrhythmia by prolonging QT intervals. The use of immunomodulatory drugs such as chloroquine (CQ) and hydroxychloroquine (HCQ) is assessed to be a therapy for COVID-19 infections. There have been no case reports of ventricular arrhythmias caused by quinine therapy in COVID-19 patients.<sup>37</sup> Previous research in patients with malaria given chloroquine therapy has identified the risk of QT interval extension and increased risk of Torsade de Pointes (TdP). Monitoring of QT interval needs to be done in patients who received chloroquine therapy.<sup>38</sup>

From the large scale case-control study of azithromycin, there were increases of ventricular arrhythmia compared to the patients with no antibiotic, but the risk became insignificant when comparing azithromycin with amoxicillin.<sup>37</sup> Strategies for minimizing the risk of arrhythmias by monitoring the baseline QT corrected (QTc) intervals indicated if patients had QTc more than 500 msec or known congenital Long QT syndrome there is a preference to withhold the drugs that prolonged QT intervals. It is important the intervals are normalized if the patient had conditions such as hypokalemia, hypomagnesemia, fever and inflammatory state.<sup>40</sup>

### *Thromboembolic events*

A case report from Italy mentions pulmonary embolism manifestations in a female aged 75 years with severe bilateral pneumonia, and confirmed diagnosis of COVID-19 infection. The patient did not have a risk of venous thrombosis,

and clinically hemodynamically stable. Laboratory findings showed an increase in leukocytes, C-reactive proteins, troponin-I and D-dimer. Echocardiographic evaluation indicated the presence of severe hypokinetic in the right ventricle with a pressure of 60 mmHg pulmonary artery, while the doppler compression ultrasonography (CUS) at inferior extremity showed the negative result. There was a bilateral filling defect that matched signs for pulmonary embolism with dominant pulmonary consolidation in the posterior part of the lung from the CT-scan.<sup>41</sup>

The animal model of acute respiratory distress syndrome (ARDS) which was infected with a lethal dose of influenza virus demonstrated the increases of platelet aggregation, pulmonary microvascular thrombosis, endothelial damage and hyperinflammatory cytokine response. This model shows the development of thrombus under highly inflammatory conditions. Infection-mediated thrombosis may be related to the inflammatory response induced by the pathogen to the coagulation system.<sup>42</sup>

### **Short and long-term effects of COVID-19 to cardiovascular disease**

For the short-term period during this pandemic time, many hospitals have advised postponing non-critical outpatient visits, defer elective cardiac procedures and surgeries. This condition led to a positive impact on the utilization of technology and the development of virtual clinics. Home-based cardiac rehabilitation with smartphone applications or trackers may be one of the options for delivering programs. In the other hand, the risk of being exposed to COVID-19 in the pandemic period may cause a delay in a patient with cardiac emergencies presented to the hospital which likely contributes to cardiac mortality and morbidity. For the long-term effects, deferred elective

diagnostic and therapeutic procedures are predicted to cause a significant impact after pandemic.<sup>28,43</sup>

Research on long-term cardiac manifestations in patients who have recovered from SARS-CoV infection showed after 12 years as much as 44% of survivors have cardiovascular system abnormalities and 66% experience hyperlipidemia. They gained an overall increase in the concentration of free

fatty acids, lysophosphatidylcholine, lysophosphatidylethanolamine, and phosphatidylglycerol in serum samples compared to individuals who have never been infected with SARS-CoV. Based on the consideration that SARS-CoV-2 and SARS-CoV have many similarities of structure with the novel COVID-19, the long-term effect on the cardiovascular system in patients recovering from COVID-19 needs to be anticipated.<sup>6</sup>

TABLE 1. Review of cardiac manifestation during COVID-19 pandemic from case reports to retrospective observational studies

First Author	Type of Study	Sample Size	Pre-existing cardiac condition	Cardiac Manifestation	Outcome
Chen et al <sup>22</sup>	retrospective	274	34% of patients had hypertension, 8% had cardiovascular disease	77% of deceased patients developed acute cardiac injury and 49% had heart failure	Patients with a history of cardiovascular comorbidities were more likely to develop acute cardiac injury and heart failure
Chen et al <sup>44</sup>	Retrospective Cohort	99	40% had cardiovascular and cerebrovascular disease	13% of patients had a level of creatinine kinase increased	11% of patients died, 58% remained at the hospital, 31% discharged
Guan et al <sup>45</sup>	retrospective cohort	1099	15% had hypertension, 2.5% had coronary heart disease	25% of patients with hypertension and 37% of patients with CHD presented with severe condition	14.5% of patients with hypertension and 22.2% of patients with CHD meet primary endpoints ICU care, needs of ventilator or death)
Huang et al <sup>4</sup>	Retrospective Cohort	41	15 % had hypertension, 15% had cardiovascular disease	12% of patients had an acute cardiac injury (elevated troponin level)	80% of patients with an acute cardiac injury need ICU care
Hui et al <sup>46</sup>	retrospective	41	3 patients had hypertension, 9 patient had cardiac-related chronic diseases, 2 patient had coronary artery disease	elevation of Troponin-I level and low epicardial adipose tissue (EAT) density found in severe and critical cases as a hallmark of acute cardiac injury, 2 patients developed atrial fibrillation	not described
Liu et al <sup>1</sup>	Retrospective Study	41	4.9% hypertension, 2.4% CAD, 7.3% arrhythmia	58.5% had cardiovascular manifestation (palpitation/ chest pain, the elevation of cardiac biomarker, new abnormality on ECG including STC)	75% of patients with CVM had in-hospital adverse events, but CVM wasn't the independent predictors
Liu et al <sup>47</sup>	retrospective cohort	137	9.5% had hypertension, 7.3% had cardiovascular disease	Patients with underlying cardiovascular disease often demonstrated comorbid heart failure	cardiac outcomes not described

Ruan et al <sup>48</sup>	retrospective study	150	34.6% had hypertension, 19% had cardiovascular disease	33.8% had cardiac troponin increased	Patients with a history of cardiovascular disease all died. Some patients died of fulminant myocarditis
Shi et al <sup>26</sup>	retrospective	416	30.5% had hypertension, 10.6% had coronary heart disease, 4.1% had chronic heart failure	patients with the underlying cardiovascular disease more likely to developed acute cardiac injury	51.2% of patients with acute cardiac injury dies
Xu et al <sup>49</sup>	retrospective case series	62	8% had hypertension	92%* had creatinine kinase increased *percentage not total 100% owing to missing data)	98%* needed hospital admission, no deaths
Yang et al <sup>25</sup>	retrospective	52	10% had chronic cardiac disease	23% had an acute cardiac injury	40% of patients with underlying chronic cardiac disease and 75% of patients with acute cardiac injury are in the non-survivors' group
Zhang JJ et al <sup>50</sup>	retrospective	140	30% had hypertension, 5% had coronary heart disease, 3.6% had arrhythmia	not described	not described
Zhou et al <sup>51</sup>	Retrospective Cohort	191	30% hypertension, 8% CAD	23% had heart failure, 17% acute cardiac injury	among 54 non-survivor, 52% had heart failure and 59% acute cardiac injury
Danzi et al <sup>41</sup>	Case report	1	no strong predisposing factors for venous thromboembolism	acute pulmonary embolism confirmed by CT scan, lower limb compression ultrasonography was negative	not described
Fried et al <sup>52</sup>	case series	3	case 1: hypertension and hyperlipidemia; case 2: no pre-existing cardiac disease; case 3: non-ischemic cardiomyopathy, atrial fibrillation and hypertension; case 4: a history of a heart transplant in 2007 and taking immunosuppressive medication	case 1: presenting with STEMI with cardiogenic shock, non-obstructive coronary, work up as myopericarditis; case 2: ARDS patients developed SVT with normal LV function; case 3: acute decompensated heart failure, developed polymorphic VT; case 4: presented as pneumonia	case 1: patient recovered; case 2: patient underwent cardioversion and rescued with ECMO; case 3: patient still intubated; case 4: the patient was discharged after 5 days of hospitalization
Hu et al <sup>30</sup>	Case report	1	none	Fulminant myocarditis presented with STEMI inferior with cardiogenic shock	clinically improve after therapy if glucocorticoid and human immunoglobulin
Hua et al <sup>34</sup>	Case report	1	no cardiovascular risk factors	myopericarditis with life-threatening cardiac tamponade	improvement of hemodynamic after pericardiocentesis
Inciardi et al <sup>53</sup>	Case report	1	no pre-existing cardiac condition	myocarditis marked with increased of cardiac biomarker, a decrease of LV function and regional wall motion abnormality, normal coronary arteries	not described

Kim et al <sup>54</sup>	Case report	1	not described	21 years old female presented with respiratory and gastrointestinal symptoms. Chest X-ray showed cardiac enlargement, confirmed with CT and MRI as myocarditis	not described
Sala et al <sup>32</sup>	Case report	1	no history of hypertension or cardiac disease	presented with chest pain and dyspnea, 3D volume rendering CT-scan demonstrated clear hypokinesia of the left ventricle mid and basal segment, suggesting reverse Takotsubo syndrome, acute virus-negative myocarditis	The patient was discharged with no symptoms
Tavazzi et al <sup>55</sup>	Case report	1	not described	cardiogenic shock clinically mimicked fulminant myocarditis	patients died of septic shock after 12 days stabilization with VA-ECMO and IABP, endomyocardial biopsy demonstrated low-grade myocardial inflammation and viral particles in the myocardium suggesting either a viraemic phase or migration from the lung
Wang et al <sup>56</sup>	Case series	138	31.2% had hypertension, 14.5% had cardiovascular disease	7.2% had an acute cardiac injury, 16.7% had arrhythmia,	80% of patients with acute cardiac injury and 69.6% with arrhythmia need ICU care
Xu et al <sup>31</sup>	case report	1	not described	Interstitial mononuclear inflammatory infiltrates from heart biopsy, no heart tissue damage	death
Zeng et al <sup>27</sup>	Case report	1	no history of hypertension or cardiac disease	fulminant myocarditis	Recovered after antiviral and mechanical life support

## DISCUSSION

Acute cardiac injury marked with the increase of cardiac biomarker such as troponin-I was the most common manifestation that has been found several studies of COVID-19. In some case reports showed that abnormality of ECG and symptom mimicking ACS as the presenting complaint of the patient with COVID-19 without any pre-existing cardiac condition, and later diagnosed as myocarditis or fulminant myocarditis if accompanied with cardiogenic shock. Thromboembolic events may happen in a critically ill patient with a severe infection of pneumonia because of local

thrombosis in the pulmonary artery caused by the hyperinflammatory response.

Arrhythmia in COVID-19 patients may be precipitate of electrolyte imbalance due to critically ill patient and worsened with the interaction with COVID-19 therapy. There is a lack of data in the incidence of type 1 myocardial infection in COVID-19, the available evidence still considered type 2 myocardial infarction was the most common subtype of ACS in viral infection. There is a limitation related the exact mechanism of the effects from SARS-CoV-2 infection on cardiovascular system and its long-term effects because

of this new emerging disease. Moreover, in this outbreak condition is hard to obtain data with better level of evidence than cohort studies and case reports.

## CONCLUSION

Based on published retrospective studies and case reports, cardiac manifestations may present as the chief complaints or comorbidities in patients with COVID-19. Clinical signs and symptoms are varying from the asymptomatic, rise of the cardiac marker, acute cardiac injury, worsening of pre-existing cardiac condition, ischemia, heart failure, thromboembolic event, arrhythmia, fulminant myocarditis to fatal cardiogenic shock. COVID-19 infection can cause many interactions in the cardiovascular system, whether the patients already had chronic heart disease or not. There are several hypotheses related to the mechanisms of cardiac manifestation in patients with coronavirus infection, including damage to ACE2 receptors, hypoxia, cardiac microvascular damage, electrolyte imbalance, drug interaction and increased inflammatory response. Considering the lack of evidence of the RAS inhibitor in COVID-19, the use of ACE inhibitor/ARB should be continued unless contraindicated and may be beneficial in patients with hypertension, heart failure and diabetes mellitus. Because of this is a new emerging disease, long term studies related to cardiovascular manifestation and therapy in COVID-19 survivors are still needed to give a better understanding of the disease. Early recognition of cardiac manifestations from patients with COVID-19 infection will be the key to prevent short and long term cardiac adverse events.

## ACKNOWLEDGEMENTS

The authors would like to thank all staff and residents of the Department

of Cardiology and Vascular Medicine, Faculty of Medicine, Public Health and Nursing, Universitas Gadjah Mada, for the discussion and suggestions regarding cardiac manifestations in the COVID-19 period.

## REFERENCE

1. Liu R, Ming X, Zhu H, Song L, Gao Z, Gao L, *et al.* Association of cardiovascular manifestations with in-hospital outcomes in patients with COVID-19: A hospital staff data. *Med Rxiv* 2020; (26):3-14. <https://doi.org/10.1101/2020.02.29.20029348>
2. Hoffmann M, Kleine-Weber H, Schroeder S, Krüger N, Herrler T, Erichsen S, *et al.* SARS-CoV-2 cell entry depends on ACE2 and TMPRSS2 and is blocked by a clinically proven Protease Inhibitor. *Cell* 2020; 1-10. <https://doi.org/10.1016/j.cell.2020.02.052>
3. WHO. Coronavirus disease (COVID-2019) Situation Report - 132. WHO. 2020.
4. Huang C, Wang Y, Li X, Ren L, Zhao J, Hu Y, *et al.* Clinical features of patients infected with 2019 novel coronavirus in Wuhan, China. *Lancet* 2020; 395(10223):497-506. [https://doi.org/10.1016/S0140-6736\(20\)30183-5](https://doi.org/10.1016/S0140-6736(20)30183-5)
5. ACC. COVID-19 clinical guidance for the cardiovascular care team. *American College of Cardiology* 2020; 1-4.
6. Zheng YY, Ma YT, Zhang JY, Xie X. COVID-19 and the cardiovascular system. *Nat Rev Cardiol* 2020; 17:259-60. <https://doi.org/10.1038/s41569-020-0360-5>
7. Sellers SA, Hagan RS, Hayden FG, Fischer WA. The hidden burden of influenza: A review of the extra-pulmonary complications of influenza infection. *Influenza Other Respi Viruses* 2017; 11(5):372-93 <https://doi.org/10.1111/irv.12470>

8. Nguyen JL, Yang W, Ito K, Matte TD, Shaman J, Kinney PL. Seasonal influenza infections and cardiovascular disease mortality. *JAMA Cardiol* 2016; 1(3):274-81.  
<https://doi.org/10.1001/jamacardio.2016.0433>
9. Xiong T, Redwood S, Prendergast B, Chen M. Coronaviruses and the cardiovascular system: acute and long-term implications. *Eur Heart J* 2020; 41(19):1798-800.  
<https://doi.org/10.1093/eurheartj/ehaa231>
10. Wu D, Wu T, Liu Q, Yang Z. The SARS-CoV-2 outbreak: What we know. *Int J Infect Dis* 2020; 94:44-8.  
<https://doi.org/10.1016/j.ijid.2020.03.004>
11. Meo SA, Alhowikan AM, Al-Khlaiwi T, Meo IM, Halepoto DM, Iqbal M, et al. Novel coronavirus 2019-nCoV: prevalence, biological and clinical characteristics comparison with SARS-CoV and MERS-CoV. *Eur Rev Med Pharmacol Sci* 2020; 24(4):2012-9.
12. Li G, Fan Y, Lai Y, Han T, Li Z, Zhou P, et al. Coronavirus infections and immune responses. *J Med Virol* 2020; 92(4):424-32.  
<https://doi.org/10.1002/jmv.25685>
13. Zhang H, Penninger JM, Li Y, Zhong N, Slutsky AS. Angiotensin-converting enzyme 2 (ACE2) as a SARS-CoV-2 receptor: molecular mechanisms and potential therapeutic target. *Intensive Care Med* 2020; 46(4):586-90.  
<https://doi.org/10.1007/s00134-020-05985-9>
14. Tikellis C, Thomas MC. Angiotensin-converting enzyme 2 (ACE2) is a key modulator of the renin angiotensin system in health and disease. *Int J Pept* 2012; 2012:256294.  
<https://doi.org/10.1155/2012/256294>
15. Nicin L, Abplanalp WT, Mellentin H, Katthi B, Tombor L, John D, et al. Cell type specific expression of the putative SARS-CoV-2 receptor ACE2 in human hearts. *Eur Heart J* 2020; ehaa311.  
<https://doi.org/10.1093/eurheartj/ehaa311>
16. Kuster GM, Osswald S, Haaf P, Widmer AF. SARS-CoV2: should inhibitors of the renin - angiotensin system be withdrawn in patients with COVID-19? *Eur Heart J* 2020; 41(19):1801-3.  
<https://doi.org/10.1093/eurheartj/ehaa235>
17. South AM, Tomlinson L, Edmonston D, Hiremath S, Sparks MA. Controversies of renin-angiotensin system inhibition during the COVID-19 pandemic. *Nat Rev Nephrol* 2020; 19:6-8.  
<https://doi.org/10.1038/s41581-020-0279-4>
18. Bavishi C, Maddox TM, Messerli FH. Coronavirus disease 2019 (COVID-19) infection and renin angiotensin system blockers. *JAMA Cardiol* 2020; 19(8):1965-74.  
<https://doi.org/10.1001/jamacardio.2020.1282>
19. Vaduganathan M, Vardeny O, Michel T, McMurray JJV, Pfeffer MA, Solomon SD. Renin-angiotensin-aldosterone system inhibitors in patients with Covid-19. *N Engl J Med* 2020; 382:1653-9.  
<https://doi.org/10.1056/NEJMsr2005760>
20. Chen L, Li X, Chen M, Feng Y, Xiong C. The ACE2 expression in human heart indicates new potential mechanism of heart injury among patients infected with SARS-CoV-2. *Cardiovasc Res* 2020; cvaa078.  
<https://doi.org/10.1093/cvr/cvaa078>
21. Horn EM, Failure AH, Vascular P, Programs D, Chakinala M, Oudiz R, et al. Could pulmonary arterial hypertension (PAH) patients be at a lower risk from severe COVID-19? *Pulm Circ* 2020; 10(2): 2045894020922799.  
<http://doi.org/10.1177/2045894020922799>
22. Chen T, Wu D, Chen H, Yan W, Wang T, Guo W, et al. Clinical characteristics of 113 deceased patients with coronavirus disease 2019: retrospective study. *BMJ* 2020; 368.  
<https://doi.org/10.1136/bmj.m1091>
23. Li B, Yang J, Zhao F, Zhi L, Wang X, Liu L, et al. Prevalence and impact of

- cardiovascular metabolic diseases on COVID-19 in China. *Clin Res Cardiol* 2020; 109(5):531-8.  
<https://doi.org/10.1007/s00392-020-01626-9>
24. Siddiqi HK, Mehra MR. COVID-19 illness in native and immunosuppressed states: a clinical-therapeutic staging proposal. *J Hear Lung Transplant* 2020; 39(5): 405-7.  
<https://doi.org/10.1016/j.healun.2020.03.012>
25. Yang X, Yu Y, Xu J, Shu H, Xia J, Liu H, *et al.* Clinical course and outcomes of critically ill patients with SARS-CoV-2 pneumonia in Wuhan, China: a single-centered, retrospective, observational study. *Lancet Respir Med* 2020; 2600(20):1-7.  
[https://doi.org/10.1016/S2213-2600\(20\)30079-5](https://doi.org/10.1016/S2213-2600(20)30079-5)
26. Shi S, Qin M, Shen B, Cai Y, Liu T, Yang F, *et al.* Association of Cardiac Injury with Mortality in Hospitalized Patients with COVID-19 in Wuhan, China. *JAMA Cardiol* 2020; e200950.  
<https://doi.org/10.1001/jamacardio.2020.0950>
27. Zeng J-H, Liu Y-X, Yuan J, Wang F-X, Wu W-B, Li J-X, *et al.* First case of COVID-19 infection with fulminant myocarditis complication: case report and insights. *Infection* 2020; 1-5.  
<https://doi.org/10.20944/preprints202003.0180.v1>
28. Guzik TJ, Mohiddin SA, Dimarco A, Patel V, Savvatis K, Marelli-Berg FM, *et al.* COVID-19 and the cardiovascular system: implications for risk assessment, diagnosis, and treatment options. *Cardiovasc Res* 2020; cvaa106.  
<https://doi.org/10.1093/cvr/cvaa106>
29. Bansal M. Cardiovascular disease and COVID-19. *Diabetes Metab Syndr Clin Res Rev* 2020; 14(3):247-50.  
<https://doi.org/10.1016/j.dsx.2020.03.013>
30. Hu H, Ma F, Wei X, Fang Y. Coronavirus fulminant myocarditis treated with glucocorticoid and human immunoglobulin. *Eur Heart J* 2020; ehaa190.  
<https://doi.org/10.1093/eurheartj/ehaa190>
31. Xu Z, Shi L, Wang Y, Zhang J, Huang L, Zhang C, *et al.* Pathological findings of COVID-19 associated with acute respiratory distress syndrome. *Lancet Respir Med* 2020; 2600(20):19-21.  
[https://doi.org/10.1016/S2213-2600\(20\)30076-X](https://doi.org/10.1016/S2213-2600(20)30076-X)
32. Sala S, Peretto G, Gramegna M, Palmisano A, Villatore A, Vignale D, *et al.* Acute myocarditis presenting as a reverse Tako-Tsubo syndrome in a patient with SARS-CoV-2 respiratory infection. *Eur Heart J* 2020; 41(19):1861-2.  
<https://doi.org/10.1093/eurheartj/ehaa286>
33. Caforio ALP, Malipiero G, Marcolongo R, Iliceto S. Myocarditis: a clinical overview. *Curr Cardiol Rep* 2017; 19(7):63.  
<https://doi.org/10.1007/s11886-017-0870-x>
34. Hua A, O'Gallagher K, Sado D, Byrne J. Life-threatening cardiac tamponade complicating myo-pericarditis in COVID-19. *Eur Heart J* 2020; ehaa253  
<https://doi.org/10.1093/eurheartj/ehaa253>
35. Wang D, Li S, Jiang J, Yan J, Zhao C, Wang Y, *et al.* Chinese society of cardiology expert consensus statement on the diagnosis and treatment of adult fulminant myocarditis. *Sci China Life Sci* 2019; 62(2):187-202.  
<https://doi.org/10.1007/s11427-018-9385-3>
36. Chen D, Li X, Song Q, Hu C, Su F, Dai J. Hypokalemia and clinical implications in patients with coronavirus disease 2019 (COVID-19). *Med Rxiv* 2020; 2019:2020.02.27.20028530.  
<https://doi.org/10.1101/2020.02.27.20028530>
37. Simpson S, Kay FU, Abbara S, Bhalla S, Chung JH, Chung M, *et al.* Radiological society of North America expert consensus statement on reporting chest CT findings related to COVID-19. Endorsed by the society of thoracic radiology, the American College of Radiology, and RSNA. *J Thorac Imaging* 2020; 10.1097/RTI.0000000000000524.



- <https://doi.org/10.1097/RTI.0000000000000524>
38. WHO Evidence Review Group. The cardiotoxicity of antimalarials. WHO/HTM/GMP/MPAC/2017.2. Geneva: World Health Organization, 2017.
  39. Trifirò G, De Ridder M, Sultana J, Oteri A, Rijnbeek P, Pecchioli S, *et al*. Use of azithromycin and risk of ventricular arrhythmia. *CMAJ* 2017; 189(15):E560-8.  
<https://doi.org/10.1503/cmaj.160355>
  40. Roden DM, Harrington RA, Poppas A, Russo AM. Considerations for drug interactions on QTc in exploratory COVID-19 (coronavirus disease 2019) treatment. *Circulation* 2020.  
<https://doi.org/10.1161/CIRCULATIONAHA.120.047521>
  41. Danzi GB, Loffi M, Galeazzi G, Gherbesi E. Acute pulmonary embolism and COVID-19 pneumonia: a random association? *Eur Heart J* 2020; 41(19):1858.  
<https://doi.org/10.1093/eurheartj/ehaa254>
  42. Beristain-Covarrubias N, Perez-Toledo M, Thomas MR, Henderson IR, Watson SP, Cunningham AF. Understanding infection-induced thrombosis: lessons learned from animal models. *Front Immunol* 2019; 10:2569.  
<https://doi.org/10.3389/fimmu.2019.02569>
  43. Yeo TJ, Wang Y-TL, Low TT. Have a heart during the COVID-19 crisis: Making the case for cardiac rehabilitation in the face of an ongoing pandemic. *Eur J Prev Cardiol* 2020; 27(9):903-5.  
<https://doi.org/10.1177/2047487320915665>
  44. Chen N, Zhou M, Dong X, Qu J, Gong F, Han Y, *et al*. Epidemiological and clinical characteristics of 99 cases of 2019 novel coronavirus pneumonia in Wuhan, China: a descriptive study. *Lancet* 2020; 395(10223):507-13.  
[https://doi.org/10.1016/S0140-6736\(20\)30211-7](https://doi.org/10.1016/S0140-6736(20)30211-7)
  45. Guan W-J, Ni Z-Y, Hu Y, Liang W-H, Ou C-Q, He J-X, *et al*. Clinical characteristics of coronavirus disease 2019 in China. *N Engl J Med* 2020; 382(18):1708-20.  
<https://doi.org/10.1101/2020.02.06.20020974>
  46. Hui H, Zhang Y, Yang X, Wang X, He B, Li L, *et al*. Clinical and radiographic features of cardiac injury in patients with 2019 novel coronavirus pneumonia. *Med Rxiv* 2020; 2020.02.24.20027052.  
<https://doi.org/10.1101/2020.02.24.20027052>
  47. Liu K, Fang Y-Y, Deng Y, Liu W, Wang M-F, Ma J-P, *et al*. Clinical characteristics of novel coronavirus cases in tertiary hospitals in Hubei Province. *Chin Med J (Engl)* 2020; 133(9):1025-31.  
<https://doi.org/10.1142/S0192415X20500445>
  48. Ruan Q, Yang K, Wang W, Jiang L, Song J. Clinical predictors of mortality due to COVID-19 based on an analysis of data of 150 patients from Wuhan, China. *Intensive Care Med* 2020; 46(5):846-8.  
<https://doi.org/10.1007/s00134-020-06028-z>
  49. Xu XW, Wu XX, Jiang XG, Xu KJ, Ying LJ, Ma CL, *et al*. Clinical findings in a group of patients infected with the 2019 novel coronavirus (SARS-CoV-2) outside of Wuhan, China: retrospective case series. *BMJ* 2020; 368:m792.
  50. Zhang JJ, Dong X, Cao YY, Yuan YD, Yang YB, Yan YQ, *et al*. Clinical characteristics of 140 patients infected with SARS-CoV-2 in Wuhan, China. *Allergy Eur J Allergy Clin Immunol* 2020; 00:1-12.  
<https://doi.org/10.1111/all.14238>
  51. Zhou F, Yu T, Du R, Fan G, Liu Y, Liu Z, *et al*. Clinical course and risk factors for mortality of adult inpatients with COVID-19 in Wuhan, China: a retrospective cohort study. *Lancet* 2020; 6736(20):1-9.  
[https://doi.org/10.1016/S0140-6736\(20\)30566-3](https://doi.org/10.1016/S0140-6736(20)30566-3)
  52. Fried JA, Ramasubbu K, Bhatt R, Topkara VK, Clerkin KJ, Horn E, *et al*. The variety of cardiovascular

- presentations of COVID-19. Circulation 2020.  
<https://doi.org/10.1161/CIRCULATIONAHA.120.047164>
53. Inciardi RM, Lupi L, Zaccone G, Italia L, Raffo M, Tomasoni D, *et al.* Cardiac involvement in a patient with coronavirus disease 2019 (COVID-19). JAMA Cardiol 2020; 2019:4-9.  
<https://doi.org/10.1001/jamacardio.2020.1096>
54. Kim I, Kim JY, Kim HA, Han S. COVID-19-related myocarditis in a 21-year-old female patient. Eur Heart J 2020; 41(19):1859  
<https://doi.org/10.1093/eurheartj/ehaa288>
55. Tavazzi G, Pellegrini C, Maurelli M, Belliato M, Sciutti F, Bottazzi A, *et al.* Myocardial localization of coronavirus in COVID-19 cardiogenic shock. Eur J Heart Fail 2020; 22(5):911-5.  
<https://doi.org/10.1002/ejhf.1828>
56. Wang D, Hu B, Hu C, Zhu F, Liu X, Zhang J, *et al.* Clinical characteristics of 138 hospitalized patients with 2019 novel coronavirus-infected pneumonia in Wuhan, China. JAMA 2020; 323(11):1061-9.  
<https://doi.org/10.1001/jama.2020.1585>