



## Neurological findings in patients with COVID-19: a systematic review

Mawaddah Ar Rochmah<sup>1\*</sup>, Sekar Satiti<sup>1</sup>, Ismail Setyopranoto<sup>1</sup>, Indra Sari Kusuma Harahap<sup>1</sup>, Desin Pambudi Sejahtera<sup>1</sup>, Dhite Bayu Nugroho<sup>2,3</sup>, Sri Sutarni<sup>1</sup>

<sup>1</sup>Department of Neurology, <sup>2</sup>Center for Clinical Epidemiology and Biostatistics Unit, <sup>3</sup>Department of Internal Medicine, Faculty of Medicine, Public Health, and Nursing, Universitas Gadjah Mada, Yogyakarta

### ABSTRACT

Submitted: 2020-04-29  
Accepted : 2020-05-14

Since the emerging of the severe acute respiratory syndrome coronavirus-2 (SARS-CoV-2) infection in Wuhan, China at the end of 2019, the coronavirus disease 2019 (COVID-19) has become pandemic for months. Due to fast increased number of the positive patients with COVID-19, SARS-CoV-2 is considered highly pathogenic virus with various clinical presentations. Apart from the typical respiratory symptoms, neurological complains in COVID-19 involving central and peripheral nervous systems have been reported. This paper aimed to review the neurological findings reported in patients with COVID-19. We qualitatively reviewed studies reporting COVID-19 patient(s) with neurological manifestations according to the recommendations of PRISMA statement. There were twelve studies included in this brief review. We found that patients with neurological findings were reported ranging from symptomatic complain of headache and dizziness to specific neurological diseases/syndromes, such as meningitis/encephalitis, acute cerebrovascular diseases, Guillain-Barré syndrome, and Miller Fisher syndrome. This review suggests the possible neurological involvement in COVID-19. We hope to raise the awareness of the health workers in taking care of the patients with COVID-19 and neurological diseases.

### ABSTRAK

Sejak pertama kali muncul di Wuhan, Cina di akhir bulan Desember tahun 2019, infeksi *severe acute respiratory syndrome coronavirus-2* (SARS-CoV-2) atau *coronavirus disease 2019* (COVID-19) telah menjadi pandemic selama berbulan-bulan. Karena cepatnya penambahan jumlah pasien COVID-19, SARS-CoV-2 dinyatakan sebagai patogen poten dengan berbagai manifestasi klinis. Selain gejala pernapasan yang khas muncul pada COVID-19, penyakit ini juga dilaporkan menyebabkan gangguan saraf pusat dan perifer pada beberapa kasus. Makalah ini menelaah temuan neurologis yang dilaporkan pada pasien COVID-19. Makalah ini merupakan review kualitatif dari laporan/dokumen yang memaparkan manifestasi neurologis pada pasien COVID-19 sesuai dengan rekomendasi PRISMA. Terdapat 12 dokumen yang diikutkan dalam review ini. Temuan neurologis yang dilaporkan pada pasien COVID-19 berkisar dari keluhan klinis seperti nyeri kepala dan pusing berputar hingga penyakit/sindrom neurologis spesifik seperti meningitis/encephalitis, penyakit serebrovaskular akut, sindrom Guillain-Barré, dan sindrom Miller Fisher. Dapat disimpulkan kemungkinan adanya keterlibatan masalah neurologis pada pasien COVID-19. Diharapkan agar setiap tenaga kesehatan yang merawat pasien COVID-19 dan penyakit saraf untuk selalu waspada.

**Keywords:**  
SARS-CoV-2;  
COVID-19;  
neurological findings;  
nervous system;

## **INTRODUCTION**

Since it was firstly reported in Wuhan, China in December 2019, the novel coronavirus, as recently well-known as severe acute respiratory syndrome coronavirus-2 (SARS-CoV-2), infection has spread throughout the world. As of April 26<sup>th</sup>, 2020, the cases update of coronavirus disease 2019 (COVID-19) has reached the number of 2,989,420 infected people with case fatality rate of 6.91%, globally.<sup>1</sup> Among other family of this single-stranded RNA virus infections, the world has experienced, the outbreaks of SARS-CoV in 2002 and MERS (middle east respiratory syndrome) in 2012, SARS-CoV-2 infection is the most devastating one that makes World Health Organization (WHO) announced it as a pandemic on March 12<sup>th</sup>, 2020. In Indonesia, the number of COVID-19 patients keep rising up to 8,882 positive cases with 8.36% case fatality rate in less than two months after the first confirmed case was firstly reported on March 2<sup>nd</sup>, 2020.<sup>2</sup>

Due to the fast spread of the virus, SARS-CoV-2 is considered as highly pathogenic with researches on its transmission, natural course and clinical presentation, high throughput diagnosis, and possible treatments regiment are currently advancing. Several studies on COVID-19 showed various spectrum of clinical presentations ranging asymptomatic infection; typical respiratory symptoms of fever, cough, fatigue, sputum production, shortness of breath, sore throat, myalgias or arthralgias; gastrointestinal symptoms of diarrhea, nausea, vomiting; and some neurological features as headache, impairment of consciousness, anosmia, and ageusia.<sup>3-5</sup> Although the precise natural course and pathogenesis of COVID-19-induced neurological manifestations remained to be elucidated, some studies on neurological manifestations, complications, and

syndromes in patients with COVID-19 have been published. Therefore, all health workers should be aware that patients with COVID-19 might present with neurological manifestations or patients with neurological complains might be positive for COVID-19. Here, we presented a brief review on the neurological findings from studies and reports of COVID-19 patients to raise the awareness of the possible neurological involvement in this disease.

## **MATERIALS AND METHODS**

This study is a qualitative systematic review following the recommendations of the Preferred Reporting Items for Systematic Reviews and Meta-Analyses (PRISMA) statement (FIGURE 1).<sup>6</sup> The review protocol in this study was not previously registered. Our search methods were performed in MEDLINE (accessed via PubMed) to display electronic databases from December 1<sup>st</sup>, 2019 to April 24<sup>th</sup>, 2020. We systematically searched published articles by implementing the following keywords: central nervous system [Title/Abstract] OR peripheral nervous system [Title/Abstract] OR *neuro\**[Title/Abstract] OR *nerve\**[Title/Abstract] OR *encephal\**[Title/Abstract] OR *mening\**[Title/Abstract] AND nCoV[all] OR 2019-nCoV[all] OR new coronavirus[all] OR novel coronavirus[all] OR covid19[all] OR COVID-19[all] OR SARS-CoV-2[all]. All articles published in English were included. The authors also screened the references list of the included studies or relevant reviews to ensure other documents indexed by other indexing databases were included. Each article was screened and studied by two authors (MA and DBN) independently whether it met the inclusion criteria: any documents explaining neurological findings from patient(s) with COVID-19 (including original article, case reports, case series, letter to editor or

correspondence), full article written in English, and published within December 1<sup>st</sup>, 2019 to April 24<sup>th</sup>, 2020. The titles and abstracts of the yielded search were screened against the inclusion criteria, further full texts of any uncertain studies were obtained for screening. In regards to the recommendations of PRISMA statement, we excluded a systematic review regarding central nervous system manifestations of COVID-19. If there is any disagreement between the two authors, a third author was invited for discussion to resolve the problems. None of the authors were blind to the study titles, authors, and their institutions. The following data were extracted from the included studies: study authors, study designs, subjects studied, results in neurological findings both clinical and supporting examinations data, limitations, and level of evidence according to Oxford Centre for Evidence-Based Medicine levels of evidence.<sup>7</sup> Quantitative analysis is performed whenever possible. Since we used secondary data that has been

published, ethical clearance was not required for this study.

## RESULTS

### Systematic search results

Using the applied search methods, we found a total of 68 retrieved articles from the electronic database. After screening the articles by reading the abstracts, six articles were excluded due to its irrelevance and language (not in English). Full-texts were then assessed further to include only firstly reported COVID-19 patient(s)' neurological findings. As a result, another 53 articles were eliminated. Of the nine remaining articles, we went through the detailed of each study, including its references list. From their references lists, we included three more eligible studies. Finally, there were twelve articles to answer our research question on the neurological findings in patients with COVID-19 (FIGURE 1).

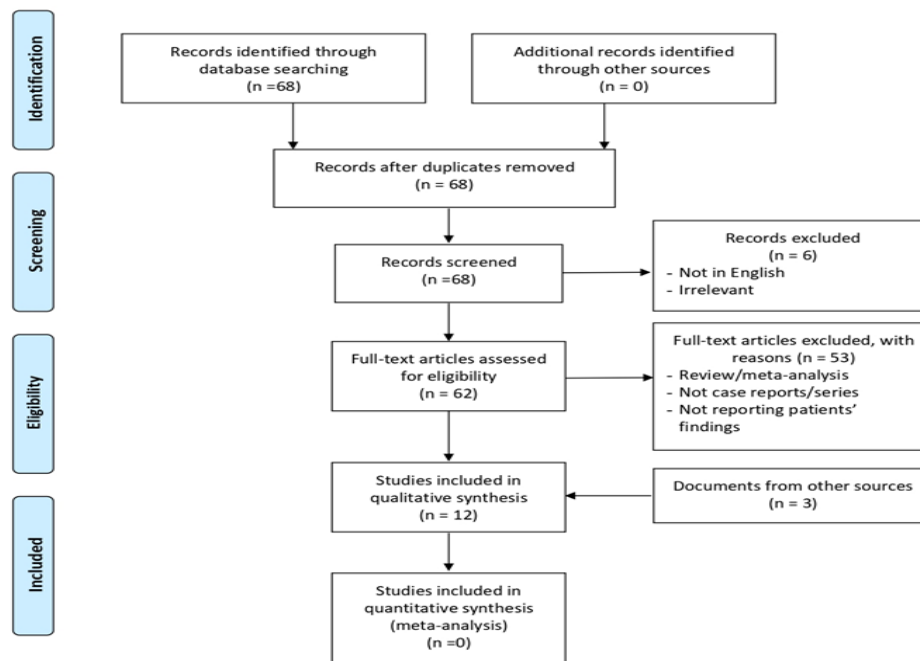


FIGURE 1. Preferred reporting items for systematic reviews and meta-analyses (PRISMA) diagram flow of this study

Among twelve included studies, three articles were original article with retrospective, observational methods, three articles were case reports or case series, and the other six articles were letter to editor or correspondence. All articles reported the neurological findings in patient(s) with COVID-19, both specifically and generally. In cases with specific neurological diseases

or syndromes, we then categorized them into findings on meningitis/encephalitis, acute cerebrovascular diseases, neuromuscular disease, and seizure. Apart from the abovementioned diseases or syndromes, the findings were categorized into other neurological findings. All extracted data were summarized in TABLE 1.

TABLE 1. Neurological findings reported in patients who were tested positive for COVID-19

Author/Year	Patients / Subjects and COVID-19 diagnosis	Methods	Neurological signs and symptoms	Supporting examinations findings	Limitations	Level of Evidence
Mao <i>et al.</i> <sup>5</sup>	214 hospitalized patients with confirmed SARS-CoV-2 infection by high throughput sequencing or Real-time PCR of throat swab specimens	Retrospective, observational, multi-center study	CNS manifestations: dizziness (16.8%), headache (13.1%), impaired consciousness (7.5%), acute cerebrovascular disease (2.8%), ataxia (0.5%), seizure (0.5%).  PNS manifestations: taste impairment (5.6%), smell impairment (5.1%), vision impairment (1.4%), nerve pain (2.3%).  Skeletal muscle injury (10.7%).	Laboratory findings:  Lower lymphocyte count, lower platelet count, and higher blood urea nitrogen level in patients with CNS symptoms.  Higher creatine kinase level, neutrophil count, higher C-reactive protein level, and higher D-dimer level in patients with skeletal muscle injury.  Ischemic stroke and cerebral hemorrhage were examined by head CT-scan.	No CSF analysis, no electrophysiological studies (EEG, EMG, or ENMG), and no objective neurological examinations were reported.	IIIb
Lu <i>et al.</i> <sup>17</sup>	304 COVID-19 patients diagnosed according to <i>Diagnosis and Treatment Protocol for COVID-19 (Trial Version 6)</i> with positive nucleic acid detection.	Retrospective, observational, multi-center study	Encephalopathy / altered consciousness / mental status (2.6%), traumatic brain injury (0.3%), acute cerebrovascular disease (0.98%)	No reports on the laboratory findings between patients with and without neurological symptoms.	No EEG examinations and no further longitudinal evaluation on seizure were recorded.	IIIb

Moriguchi <i>et al.</i> <sup>8</sup>	A 24-year-old male who was tested positive for SARS-CoV 2 RNA in CSF.	Case Report	<p>Headache, generalized fatigue, fever, sore throat, altered consciousness, and generalized seizure (in chronological order over 9 days).</p> <p>Neurological examinations: comatose (GCS E4V1M1), neck stiffness.</p>	<p>Laboratory findings: Increased WBC (neutrophilia with relative lymphopenia), increased C-reactive protein.</p> <p>Imaging:</p> <p>Chest X-ray: negative finding</p> <p>Head CT-scan: no brain edema</p> <p>Chest CT-scan: small ground glass opacity on right superior lobe and bilateral inferior lobes</p> <p>Brain MRI: hyperintensity along the wall of inferior horn of right lateral ventricle (DWI); hyperintense signal changes in the right mesial temporal lobe and hippocampus with slight hippocampal atrophy (FLAIR).</p> <p>CSF analysis: opening pressure &gt; 320 mmH<sub>2</sub>O, cell count 12/uL (10 MN, 2 PMN), positive for SARS-CoV 2 RNA using RT-PCR.</p>	No EEG examination and no final outcome was reported	IV
Poyiadji <i>et al.</i> <sup>18</sup>	A female in the late fifties with positive SARS-Cov-2 nucleic acid in her nasopharyngeal swab tested using Real-Time PCR.	Case Report (Images in Radiology)	Cough, fever, altered mental status (over 3 days)	<p>Laboratory findings: Influenza negative.</p> <p>CSF analysis: negative for bacterial culture and HSV-1, HSV-2, VZV, and West Nile virus.</p> <p>Head CT-scan: symmetric hypoattenuation within bilateral medial thalami with normal CT angiogram and venogram.</p> <p>Brain MRI: hemorrhagic rim enhancing lesions within bilateral thalami, medial temporal lobes, and subsular regions.</p>	No complete neurological examinations, no complete laboratory findings, no final outcome was reported.	IV

Gutierrez-Ortis <i>et al.</i> <sup>16</sup>	A 50 year-old and 39 year-old male patients with positive SARS-CoV-2 from oropharyngeal swabs tested with Real-Time PCR.	Case reports	<p>Patient 1 (50 y.o, male)</p> <p>Symptoms: cough, malaise, low back pain, fever, vertical diplopia, perioral paresthesia, gait instability (in chronological order in over 5 days). Neurological examinations: normal consciousness, no facial weakness, perioral paresthesia, no motoric and sensoric deficits, broad-based ataxic gait, no dysmetria, absent deep tendon reflexes in all extremities, right internuclear ophthalmoparesis and right fascicular oculomotor palsy.</p> <p>Patient 2 (39 y.o, male)</p> <p>Symptoms: diarrhea, low-grade fever, general weakness, diplopia, ageusia.</p> <p>Neurological examinations: normal consciousness, bilateral abducens palsy, no motoric and sensoric deficits, absent deep tendon reflexes in all extremities, no gait instability or ataxia, no dysmetria.</p>	<p>Patient 1</p> <p>Laboratory findings: lymphopenia, elevated C-reactive protein level, antibody to ganglioside GD1b-IgG.</p> <p>CSF analysis: opening pressure 110 mmH<sub>2</sub>O, WBC 0, protein 80 mg/dl, glucose 62 mg/dl, normal cytology, sterile culture, negative serologies, and negative for SARS-CoV2.</p> <p>Chest X-ray: within normal limit</p> <p>Head CT-scan: within normal limit</p> <p>Patient 2</p> <p>Laboratory findings: leukopeni.</p> <p>CSF analysis: opening pressure 100 mmH<sub>2</sub>O, WBC 2/uL, protein 62 mg/dl, glucose 50 mg/dl, normal cytology, sterile culture, negative serologies, and negative for SARS-CoV2.</p> <p>Chest X-ray: within normal limit</p> <p>Head CT-scan: within normal limit</p>	No electrophysiological studies were reported	IV
Ye <i>et al.</i> <sup>9</sup>	A Wuhan male detected positive for SARS-CoV-2.	Letter to editor/ Case report	<p>Symptoms: fever, shortness of breath, myalgia, altered consciousness (confusion).</p> <p>Neurological examinations: Positive meningeal irritation signs (nuchal rigidity, Kernig sign, Brudzinsky sign) and positive pathological reflex in lower limbs.</p>	<p>Laboratory findings: leukopenia with lymphopenia.</p> <p>CSF analysis: opening pressure 220 mmH<sub>2</sub>O, WBC 1/uL, protein 27 mg/dl, glucose 56 mg/dl, ADA 0.17 U/l.</p> <p>Head CT-scan: within normal limit</p> <p>Chest CT-scan: multiple subpleural ground glass opacities</p>	No complete patient's identity, no final outcome, and no explanation from which specimen positive SARS-CoV-2 detection were reported.	IV

Helms <i>et al.</i> <sup>12</sup>	58 patients with severe COVID-19 who were positive for SARS-CoV-2 reverse-transcriptase PCR from nasopharyngeal swab.	Letter to editor/ Case series	Positive CAM-ICU (65%), agitation (69%), corticospinal tract signs: enhanced tendon reflexes, ankle clonus, bilateral pathological reflexes in lower limbs (67%), dysexecutive syndromes: inattention, disorientation, poorly organized movement in response to command (36%)	Brain MRI (13 patients): leptomeningeal enhancement (62%), perfusion abnormalities (100%), cerebral ischemic stroke (23%).  CSF analysis (7 patients):  Oligoclonal band with the same pattern in serum (29%), elevated IgG and protein level (14%), low albumin level (57%), negative SARS-CoV-2 RT PCR (100%)	No specific explanation on patients who underwent lumbar puncture and no final outcome were reported.	IV
Duong <i>et al.</i> <sup>10</sup>	A 41 year-old female who was tested positive for COVID-19	Letter to editor/ Case report	Symptoms: headache, fever, new-onset of seizure.  Neurological examinations: worsening encephalopathy (disorientation, hallucinations, lethargic), neck stiffness, photophobia, no motoric and sensoric deficit.	Laboratory findings: no abnormality reported, negative HSV PCR  CSF analysis:  WBC 70 (100% lymphocyte), RBC 65, protein 100, glucose 120.  Head CT-scan: within normal limit  Serial chest X-ray: normal  Chest CT-scan: normal	No CSF analysis for SARS-CoV-2, no explanation from which specimen positive SARS-CoV-2 detection were reported.	IV
Yin <i>et al.</i> <sup>11</sup>	A 64 year-old male in Wuhan who was tested positive for 2019-nCoV nucleic acid from throat swab	Letter to editor/ Case report	Symptoms: fever, cough, insomnia, muscle soreness, lethargic, and unresponsive.  Neurological examinations: poor mental state, altered consciousness (lethargic, irritable), speech dissociation, positive pathological reflexes in bilateral lower limbs, positive meningeal signs (neck stiffness, Brudzinski sign).	Laboratory findings: normal WBC, slight increase in C-reactive protein level.  CSF analysis: colorless, clear, opening pressure 200 mmH <sub>2</sub> O, WBC 1/ uL, protein 27.5 mg/dl, glucose 56.5 mg/dl, negative for 2019-nCoV nucleic acid.  Head CT-scan: no significant abnormalities  Chest CT-scan: multiple ground-glass opacities with multiple fibrous cord-like shadows in both lungs.		IV

Zhao <i>et al.</i> <sup>14</sup>	A 61 year-old woman who was tested positive for SARS-CoV-2 using RT-PCR from oropharyngeal swab specimen	Correspondence/ Case report	Symptoms: acute. progressive weakness in both legs, severe fatigue, followed by fever and cough after 15 days.  Neurological examination (on arrival): progressive symmetrical weakness and areflexia in both legs, decreased sensoric function in distal extremities.	Laboratory findings: lymphopenia, thrombocytopenia.  CSF analysis: WBC 5/uL, protein 124 mg/dL.  NCS: delayed distal latencies and absent F-waves in early course, supporting demyelinating neuropathy.	No clear causality between SARS-CoV-2 infection and GBS, no microbiological testing on admission were reported	IV
Toscano <i>et al.</i> <sup>15</sup>	5 patients who were positive for COVID-19: 4 patients had positive nasopharyngeal swab of SARS-CoV-2 and 1 patient had positive serologic test for SARS-CoV-2.	Letter to Editor/ Case series	Symptoms: four patients had lower-limb weakness and paresthesia, one patient had facial diplegia followed by ataxia and paresthesia.  Neurological examinations: four patients had generalized flaccid tetraparesis/tetraplegia evolved in period of 36 hours until 4 days, three patients received mechanical ventilation.	CSF analysis: normal protein level (40%), normal WBC (100%), negative antiganglioside antibody (100%).  NCS and EMG (consistent with GBS): low compound muscle action potential (100%), prolonged motor distal latencies (40%), fibrillation potentials early (60%) late (20%).  Brain MRI: enhancement of bilateral facial nerve (20%)  Spinal MRI: enhancement of caudal nerve roots (40%)	No detailed laboratory findings were reported	IV
Li <i>et al.</i> <sup>21</sup>	221 patients with positive throat swab of SARS-CoV-2 using RT-PCR	Single-center, retrospective, observational study	Acute ischemic stroke (5%), cerebral venous sinus thrombosis (0.5%), cerebral hemorrhage (0.5%)	Laboratory findings: increased WBC, neutrophilia, lymphopenia, low platelet count, increased C-reactive protein level, increased D-dimer level, increased AST level, increased blood urea nitrogen level, and increased creatinine level.  Head CT-scan was performed to establish the diagnosis of cerebrovascular diseases.	No other neurological manifestations were reported	IIIb

SARS-CoV-2: Severe Acute Respiratory Syndrome-Coronavirus-2; PCR: Polymerase Chain Reaction; CNS: Central Nervous System; CT-scan: Computed Tomography-scan; CSF: Cerebrospinal Fluid; EEG: Electroencephalography; EMG: Electromyography; ENMG: Electroneuromyography; GCS: Glasgow Coma Scale; WBC: White Blood Cell Count; MRI: Magnetic Resonance Imaging; DWI: Diffusion Weighted Images; FLAIR: Fluid-attenuated Inversion Recovery; ADA: Adenosine Deaminase; CAM-ICU: Confusion Assessment Methods – Intensive Care Unit; NCS: Nerve conduction study; GBS: Guillain-Barré Syndrome; AST: Aspartate aminotransferase.



### **Neurological findings on meningitis and encephalitis in patients with COVID-19**

In this study, we found four reports on four positive COVID-19 patients with meningoencephalitis findings.<sup>8-11</sup> All cases showed fever and consciousness disturbance, with only three of them were preceded by respiratory complains, such as shortness of breath or cough.<sup>9-11</sup> In neurological examination, all cases showed altered consciousness, fever, and positive meningeal irritation signs. Only one case that reported generalized seizure.<sup>8</sup> In this case, brain MRI was performed showing abnormalities in patient's right mesial temporal lobe and hippocampus. All patients underwent lumbar puncture with opening pressure of more than 20 mmH<sub>2</sub>O in three studies<sup>8,9,11</sup> and all CSF analyses showed relatively normal cell count, protein level, and sugar level. Of the four cases, only one study showed negative throat swab of SARS-CoV-2 despite the presence of respiratory symptoms but positive CSF SARS-CoV-2.<sup>8</sup> However, one case showed positive throat swab of SARS-CoV-2 despite the absence of respiratory complains but negative CSF SARS-CoV-2.<sup>10</sup> Follow up for these cases showed that the neurological symptoms of three patients with positive throat swab of SARS-CoV-2 improved following their recovery from the respiratory distress or after being given hydroxychloroquine.<sup>9-11</sup>

### **Neurological findings on acute cerebrovascular diseases in patients with COVID-19**

There were three included studies in this review that reported the incidence of acute cerebrovascular diseases in patients with positive SARS-CoV-2 from throat swab: 5.17%,<sup>12</sup> 5.9%,<sup>13</sup> and 2.8%.<sup>5</sup> All these studies reported that most of the patients with acute cerebrovascular diseases were suffered from severe

COVID-19. All these patients underwent brain imaging of head CT-scan or brain MRI to establish their diagnoses of acute cerebrovascular diseases following focal neurological symptoms or unexplained encephalopathic features. Most of the cerebrovascular diseases reported were ischemic stroke, others were cerebral hemorrhage and cerebral venous sinus thrombosis. In two studies, they reported increased white blood cell count (WBC), neutrophilia with lymphopenia, increased C-reactive protein level, increased D-dimer level, increased blood urea nitrogen level, and increased creatinine level were the laboratory findings in COVID-19 patients who were susceptible for having cerebrovascular diseases.<sup>5,13</sup>

### **Neurological findings on neuromuscular diseases in patients with COVID-19**

Our search found three included studies that reported specific neuromuscular diseases in COVID-19 patients. Two studies reported Guillain-Barré syndrome (GBS) and one study reported Miller Fisher syndrome and polyneuritis cranialis in COVID-19 patients.<sup>14-16</sup> Zhao *et al.*<sup>14</sup> reported a case of GBS in which the classic neurological symptoms of GBS with acute progressive limbs weakness and distal paresthesia preceding the characterized respiratory symptoms of COVID-19. Toscano *et al.*<sup>15</sup> reported five cases of GBS with initial symptoms of lower limb weakness and paresthesia in four patients and facial diplegia in another patient that following the onset of COVID-19 symptoms ranged from 5 to 10 days. Gutiérrez-Ortiz *et al.*<sup>16</sup> reported a patient with classical triad of Miller-Fisher: ophthalmoplegia, ataxia, and limbs areflexia after developing fever, cough, malaise, and headache; and another patient with bilateral abducens palsy and ageusia after presenting with low-grade fever and diarrhea. All

patients were tested positive for SARS-CoV-2 from their throat swabs, except for one case with GBS whose SARS-CoV-2 PCR were negative but positive for the virus serologic test.<sup>15</sup> All patients underwent lumbar puncture, with most results showed marked increased in CSF protein level (TABLE 1). Only studies reporting GBS patients reported the nerve conduction study whose results were consistent with demyelinating neuropathy and axonal variant.<sup>14,15</sup> In laboratory findings, antiganglioside antibodies were found negative in all the tested samples in GBS patients and positive for antibody GD1b-IgG in a patient with Miller-Fisher syndrome.<sup>15,16</sup> All patients in these reports, except for the one with polyneuritis cranialis, were treated using intravenous immunoglobulin. During the follow up, only two patients showed poor outcomes while the other patients resolved.<sup>15,16</sup>

### **Neurological findings on seizure in patients with COVID-19**

We found two included studies that reported about seizure. A study reported the seizure incidence of 0.5% as one of the neurological manifestations in patients who were positive for SARS-CoV-2 from throat swab specimen.<sup>5</sup> However, this report was only based on clinical presentation of the patient without any further explanation regarding the seizure semiology or past history of epilepsy and further examinations of EEG (electroencephalography) or other brain imaging. In another study, it was reported that no new-onset seizure or status epilepticus following the diagnosis of COVID-19 in 304 patients.<sup>17</sup> Two seizure-like events were seen in patients with acute stress reaction and hypocalcemia that resolved after being given antianxiety and calcium correction treatments, respectively. Furthermore, this study highlighted the possibility for COVID-19 patients, particularly the

ones with severe infections, for having acute symptomatic seizures as they have substantial risk factors such as hypoxia, shock, sepsis, multiorgan dysfunction syndrome, imipenem use, acute cerebrovascular disease, electrolyte imbalance, etc.

### **Other neurological findings in patients with COVID-19**

In a study reported by Mao *et al.*<sup>5</sup> other than the above-mentioned neurological manifestations, some of these symptoms should be put into account: dizziness (16.8%), headache (13.1%), impaired consciousness (7.5%), ataxia (0.5%), taste impairment (5.6%), smell impairment (5.1%), vision impairment (1.4%), nerve pain (2.3%), and skeletal muscle injury (10.7%). This study also found increased creatinine kinase level in COVID-19 patients with skeletal muscle complains, regardless the severity. In other study, a case about acute necrotizing encephalopathy was reported from a female in her late 50's with acute fever, cough, and altered mental status.<sup>18</sup> Her throat swab was positive for SARS-CoV-2 nucleic acid. Her brain MRI confirmed the hemorrhagic rim enhancing lesions in bilateral thalami, medial temporal lobes, and subinsular regions. This report showed the rare complication of acute necrotizing encephalopathy that might be associated with SARS-CoV-2 infection. In severe COVID-19 patients with intensive care treatments, some neurologic signs that can be found in these patients are delirium with positive Confusion Assessment Methods – Intensive Care Unit (44%), agitation (69%), corticospinal tract signs (67%), and dysexecutive syndrome (24%).<sup>12</sup>

### **DISCUSSION**

Our results showed the various neurological findings from patients with

COVID-19 reported in several studies suggesting the possible neurological involvement of the disease. However, the mechanisms on how SARS-CoV-2 could reach the central or peripheral nervous system are still widely studied. A study showed that angiotensin-converting enzyme-2 (ACE2) was found as the functional receptor for SARS-CoV-2, sharing the same receptor as SARS-CoV.<sup>19</sup> ACE2 is widely distributed in human body, including epithelial cells of alveoli, nasal mucous, gastrointestinal tracts, and also endothelial cells of the brain.<sup>20</sup> As its functional receptors are ubiquitously distributed throughout the human body, SARS-CoV-2 infections may show various clinical presentations, including nervous system manifestations.

The neuroinvasion potential of SARS-CoV-2 has been considered. This virus might ascend to reach the central nervous system (CNS) through olfactory nerves causing anosmia and its inflammatory immune response may affect the taste buds leading to ageusia.<sup>4,16,21</sup> It might explain the invasion of SARS-CoV-2 to the central nervous systems. However, our study found that out of twenty COVID-19 patients who underwent lumbar puncture for CSF analyses due to the presenting neurological signs and symptoms, only eleven samples were further tested for SARS-CoV-2 nucleic acid with only one case was reported positive for SARS-CoV-2.<sup>8-12,14-18</sup> This patient was tested negative for SARS-CoV-2 from his nasopharyngeal swab sample but positively tested for SARS-CoV-2 from his CSF sample,<sup>8</sup> while the other cases were reported otherwise. It might be due to the low viral titer in CSF and the SARS-CoV-2 dissemination is transient showed by the undetected anti-SARS-CoV-2 IgM and IgG in CSF sample of the COVID-19 patient.<sup>9</sup> The exact mechanisms of immune response to SARS-CoV-2 is still widely studied since people may react differently to the disease, leading to mild COVID-19

manifestations or critical/severe cases that often lead to mortality. Apart from the highly deleterious effect of the virus itself, several hypotheses regarding the immune responses in COVID-19 include the hyperinflammation that resemble cytokine release syndrome/cytokine storm in severe COVID-19 patients, the increased coagulopathy that might contribute to the fatality of COVID-19, the different of IgG and IgM levels among COVID-19 patients according to the disease severities, and possible autoimmune response that might trigger delayed complications from initial symptoms.<sup>22-24</sup> All cases in our study reported that the neurological signs and symptoms were developed during acute phase of the disease, only day(s) since the initial fever and cough (TABLE 1). Further investigation is necessary to elucidate the role of immune response to COVID-19 in the development of neurological manifestations.

All the COVID-19 patients who were reported with specific neurological manifestations underwent supportive examinations to confirm the diagnosis. For instance, patients with meningitis/encephalitis showed the supporting clinical examinations of fever, altered consciousness, and CSF analysis that supported the findings of viral infection.<sup>8-11</sup> All patients with cerebrovascular diseases were found with focal or global neurological deficits and confirmed with cerebral imaging, such as head CT-scan or cerebral MRI.<sup>5,12,13</sup> Patients that had cerebrovascular diseases were reported to have severe COVID-19 manifestations, higher serum D-dimer level, higher WBC with neutrophilia and lymphopenia, and higher C-reactive protein level.<sup>5,13</sup> Patients that were reported with neuromuscular diseases, such as GBS, Miller Fisher syndrome, and polyneuritis cranialis, showed typical symptoms of the diseases, underwent CSF analysis that mostly showed increased protein

level, electrophysiological studies to see the findings to support peripheral nerve disease, and mostly received intravenous immunoglobulin therapy.<sup>14-16</sup> Although only few cases of new-onset seizure were reported, clinicians should always be cautious to the COVID-19 patients that showed potential risk factors for seizure, such as hypoxia, shock, sepsis, and electrolyte imbalance.<sup>17</sup> Only patients that reported in case series, case reports, letter to editor, or correspondence that were examined thoroughly from its clinical, laboratory, and imaging findings. The included retrospective, observational studies that involved many patients did not report the full work up of the patients, except all patients reported with cerebrovascular diseases were established with head CT-scan or brain MRI.

This review suggested the possible neurological involvement in patients with COVID-19. The neurological findings ranging from symptoms such as headache and dizziness to some established specific neurological diseases/syndromes, such as meningitis/encephalitis, cerebrovascular diseases, GBS, and Miller Fisher syndromes. Whether the association of these neurological findings to COVID-19 is causative or coincidental needs further study. For instance, the pathogenesis of GBS and Miller Fisher Syndrome patients is thought to originate from an aberrant immune response caused by the para- or post-viral process of the preceding microorganism infections such as *Campylobacter jejuni* or cytomegalovirus. Due to the temporal relationship, studies showed that GBS and Miller Fisher Syndrome might be associated with SARS-CoV-2 infection.<sup>14-16</sup> Therefore, intravenous immunoglobulin and plasmapheresis that were used as therapeutic agents in these patients resulted in favorable outcome.<sup>14-16</sup> A study about convalescent plasma therapy, that was collected from the

donors who had recovered from SARS-CoV-2 infections, in five severe COVID-19 patients showed decreased viral load, improved symptoms, and decreased inflammatory biomarkers such as procalcitonin, C-reactive protein, and IL-6.<sup>25</sup> Thus, intravenous immunoglobulin, convalescent plasma therapy, or plasmapheresis using high SARS-CoV-2 specific IgM-IgG antibodies or plasma derived from the donors who had recovered from SARS-CoV-2 infections should be more efficacious for patients with COVID-19-associated GBS or Miller Fisher Syndrome.

Limitations of this review were only searching the electronic databases from Medline/PubMed and continuing the search from the references list of the included studies. We only included studies that reported COVID-19 patient(s) directly from primary observations of the authors to make sure the objectivity of the reports, therefore we included all kinds of documents of observational studies, case series, case reports, letter to editors, and correspondences. Of the included studies, only three of them are retrospective, observational studies with level of evidence IIIb while the others are case series, case reports, letter to editors, and correspondences with level of evidence IV. Furthermore, the quantitative analysis was not performed in this study because of the insufficient data for pooled estimates and synthesis. Due to the rapid development of research in this area, many other studies regarding the neurological involvement in COVID-19 patients might be expected in the near future.

## **CONCLUSION**

In conclusion, neurological involvement in COVID-19 ranges from neurological symptomatic complaints to specific diseases such as meningitis/encephalitis, cerebrovascular diseases, and neuromuscular diseases such as

GBS and Miller Fisher syndrome. All health workers that take care of patients with COVID-19 and neurological diseases should be well aware of the possible neurological findings that might present. For diagnosis confirmation, supporting examinations could be performed and definitive treatments could be given with regards to protection policy and safety measure for the patients as well as the health workers. Further observational or cohort studies about neurological involvement in COVID-19 patients are necessary to be performed in a larger number of patients with multicenter basis. In addition, studies to elucidate the definitive pathophysiology of neurological involvement in COVID-19 are also necessary in conjunction with the promising therapeutic agents for the patients.

#### ACKNOWLEDGEMENT

We would like to thank all the staffs of Department of Neurology, Faculty of Medicine, Public Health, and Nursing Universitas Gadjah Mada for their supports upon the writing of this review. We would like to deliver our deepest gratitude to Cochrane Indonesia and Clinical Epidemiology and Biostatistics Unit, Faculty of Medicine, Public Health, and Nursing Universitas Gadjah Mada for assisting in the Methodology.

#### REFERENCES

1. Dadax Limited. Corona virus. 2020. Available from: <https://www.worldometers.info/coronavirus/>
2. Gugus Tugas Pecepatan Penanganan COVID-19. COVID-19. 2020. <https://www.covid19.go.id/>
3. Guan W, Ni Z, Hu T, Liang WH, Ou CQ, He JX, *et al.* Clinical characteristics of coronavirus disease 2019 in China. *N Engl J Med* 2020; 382:1708-20. <https://doi.org/10.1056/NEJMoa2002032>
4. Vaira LA, Salzano G, Deiana G, De Riu G. Anosmia and ageusia: common findings in COVID-19 patients. *Laryngoscope*. 2020. <https://doi.org/10.1002/lary.28692>.
5. Mao L, Jin H, Wang M, Yu E, Chen S, He Q, *et al.* Neurologic manifestations of hospitalized patients with coronavirus disease 2019 in Wuhan, China. *JAMA Neurol* 2020. E1-E8. <https://doi.org/10.1001/jamaneurol.2020.1127>
6. Hutton B, Salanti G, Caldwell DM, Chaimani A, Schmid CH, Cameron C, *et al.* The PRISMA extension statement for reporting of systematic reviews incorporating network meta-analyses of health care interventions: checklist and explanations. *Ann Intern Med* 2015; 162(11):777-84. <https://www.cebm.net/2009/06/oxford-centre-evidence-based-medicine-levels-evidence-march-2009/>
7. Moriguchi T, Harii N, Goto J, Harada D, Sugarawa H, Takamino J, *et al.* A first case of meningitis / encephalitis associated with. *Int J Infect Dis* 2020; 94:55-8. <https://doi.org/10.1016/j.ijid.2020.03.062>
8. Ye M, Ren Y, Lv T. Encephalitis as a clinical manifestation of COVID-19. *Brain Behav Immun* 2020; S0889-1591(20):30465-7. <https://doi.org/10.1016/j.bbi.2020.04.017>
9. Duong L, Xu P, Liu A. Meningoencephalitis without respiratory failure in a young female patient with COVID-19 patient in Downtown Los Angeles, early April 2020. *Brain Behav Immun* 2020; S0889-1591(20):30509-2. <https://doi.org/10.1016/j.bbi.2020.04.024>
10. Yin R, Lv T, Yin R, Hospital H, Feng W, Hospital H, *et al.* Concomitant neurological symptoms observed in a patient diagnosed with coronavirus disease 2019. *J Med Virol* 2019; 0-1. <https://org.org/10.1002/jmv.25888>.
11. Helms J, Kremer S, Merdji H, Clere

- Jehl R, Schenck M, Kummerlen C, *et al.* Neurologic features in severe SARS-CoV-2 infection. *N Engl J Med* 2020; NEJMc2008597  
<https://doi.org/10.1056/NEJMc2008597>
12. Li Y, Wang M, Zhou Y, Chang J, Xian Y, Mao L, *et al.* Acute cerebrovascular disease following COVID-19: a single center, retrospective, observational study. *Lancet*. 2020;19.
  13. Zhao H, Shen D, Zhou H, Liu J, Chen S. Guillain-Barré syndrome associated with SARS-CoV-2 infection: causality or coincidence? *Lancet Neurol* 2019; 19(5):383–4.  
[http://dx.doi.org/10.1016/S1474-4422\(20\)30109-5](http://dx.doi.org/10.1016/S1474-4422(20)30109-5)
  14. Toscano G, Palmerini F, Ravaglia S, *et al.* Guillain-Barré Syndrome associated with SARS-CoV-2. *N Engl J Med*, 2020.NEJMc2009191.  
<http://dx.doi.org/10.1056/NEJMc2009191>
  15. Gutiérrez-ortiz C, Méndez A, Rodrigo-Rey S, San Pedro-Murillo E, Bermerjo-Guerrero L, Gardo Manas R, *et al.* Miller Fisher syndrome and polyneuritis cranialis in COVID-19. *Neurology* 2020;241.  
<https://dx.doi.org/10.1212/WNL.0000000000009619>.
  16. Lu L, Xiong W, Liu D, Liu J, Yang D, Li N, *et al.* New-onset symptomatic seizure and risk factor in corona virus disease 2019: a retrospective multicenter study. *Epilepsia* 2020.  
<https://dx.doi.org/10.1111/epi.16524>.
  17. Poyiadji N, Shahin G, Noujai D, Stone M, Patel S, Griffith B, *et al.* COVID-19-associated acute hemorrhagic necrotizing encephalopathy: CT and MRI features. *Radiology* 2020; 201187.  
<https://dx.doi.org/10.1148/radiol.2020201187>
  18. Wang Z, Xu X. scRNA-seq profiling of human testes reveals the presence of the ACE2 receptors target for SARS-CoV-2 infection in spermatogonia, leydig and sertoli cells. *Cells* 2020; 9(4):920.  
<http://dx.doi.org/10.3390/cells9040920>
  19. Hamming I, Timens W, Bulthuis M, Lely AT, Navis GJ, Van Goor H. Tissue distribution of ACE2 protein, the functional receptor for SARS coronavirus. A first step in understanding SARS pathogenesis. *J Pathol* 2004; 203(2):631–7.  
<https://doi.org/10.1002/path.1570>
  20. Li YC, Bai WZ, Hashikawa T. The neuroinvasive potential of SARS-CoV-2 may play role in the respiratory failure of COVID-19 patients. *J Med Virol* 2020.  
<http://doi.org/10.1002/jmv.25728>.
  21. Amiral J, Vissac AM, Seghatcian. COVID-19, induced activation of homeostasis, and immune reactions: Can an auto-immune reaction contribute to the delayed severe complications observed in some patients? *Transfus Apher Sci* 2020; 102804.  
<https://doi.org/10.1016/j.transci.2020.102804>
  22. Merad M, Martin JC. Pathological inflammation in patients with COVID-19: a key role for monocytes and macrophages. *Nat Rev Immunol* 2020.
  23. Hou H, Wang T, Zhang B, Luo Y, Mao L, Wang F, *et al.* Detection of IgM and IgG antibodies in patients with coronavirus disease 2019. *Clin Trans Immunol* 2020; e1136.  
<https://doi.org/10.1002/cti2.1136>.
  24. Shen C, Wang Z, Zhao F, Yang Y, Li J, Yuan J, *et al.* Treatment of 5 critically ill patients with COVID-19 with convalescent plasma. *JAMA* 2020; 323(16):1582-9.